



## Ukrainian Journal of Nephrology and Dialysis

Scientific and Practical, Medical Journal

### Founders:

- State Institution «Institute of Nephrology NAMS of Ukraine»
- National Kidney Foundation of Ukraine

ISSN 2304-0238;

eISSN 2616-7352

Journal homepage: <https://ukrjnd.com.ua>

### Clinical case reports

Tetyana I. Yarmola, Olga O. Gutsalenko, Ivan P. Katerenchuk,  
Lidiya A. Tkachenko, Yulia A. Kostrikova, Viktoriia V. Talash

doi: 10.31450/ukrjnd.2(78).2023.02

### Microscopic polyangiitis hiding behind the mask of COVID-19: A case series and minireview

Poltava State Medical University, Poltava, Ukraine

### Citation:

Yarmola T, Gutsalenko O, Katerenchuk I, Tkachenko L, Kostrikova Yu, Talash V. Microscopic polyangiitis hiding behind the mask of COVID-19: A case series and minireview. Ukr J Nephrol Dial. 2023;2(78):5-21. doi: 10.31450/ukrjnd.2(78).2023.02.

**Summary.** *Microscopic polyangiitis (MPA) is one of the three clinical phenotypes of vasculitis associated with antineutrophil cytoplasmic antibodies (ANCA). Although MPA is considered a rare form of ANCA-associated vasculitis (AAV), clinical evidence shows that it is fairly common among nephrologists, as it manifests as a systemic, weak-immune vasculitis affecting glomerular capillaries, resulting in necrotizing glomerulonephritis (GN) diagnosed in nearly 100% of MPA patients. The issue of AAV in general, and MPA specifically, has gained significant importance in the context of the ongoing SARS-CoV-2 coronavirus pandemic, as both conditions share common anatomical sites of infection and inflammation. This study presents three new cases of MPA in post-COVID-19 patients. The analysis and presentation encompassed demographic data, patient history regarding comorbidities, details of follow-up care, chronology with COVID-19, and laboratory findings at the time of MPA diagnosis. A comparative analysis of the chronological progression of MPA in the documented clinical cases reveals the polymorphic nature of early-stage clinical manifestations, as well as diverse patterns of disease progression in the advanced stage. Additionally, we provide a brief literature review on diagnostic challenges, pathogenetic mechanisms underlying the relationship between SARS-CoV-2 and AAV, and peculiarities of clinical presentations in early and advanced stages of MPA.*

**Key words:** *microscopic polyangiitis, COVID-19, rapidly progressive glomerulonephritis, clinical picture*

**Conflict of interest.** The authors declare no conflict of interest.

© T.I. Yarmola, O.O. Gutsalenko, I.P. Katerenchuk, L.A. Tkachenko,  
Yu.A. Kostrikova, V.V. Talash, 2023.

Correspondence should be addressed to Tetyana Yarmola: [tyarmola@gmail.com](mailto:tyarmola@gmail.com)

### Article history:

Received January 31, 2023

Received in revised form  
February 18, 2023

Accepted February 21, 2023



© Ярмола Т. І., Гуцаленко О. О., Катеренчук І. П., Ткаченко Л. О., Кострікова Ю. А., Талаш В. В., 2023.

УДК: 616.611-002:[616.98:578.834] -07-08

Т.І. Ярмола, О.О. Гуцаленко, І. П. Катеренчук, Л. О. Ткаченко, Ю. А. Кострікова, В. В. Талаш

## Мікроскопічний поліангіїт, що ховається за маскою COVID-19: серія випадків та мініогляд

Полтавський державний медичний університет, Полтава, Україна.,

**Резюме.** Мікроскопічний поліангіїт (МПА) – один із трьох клінічних фенотипів васкулітів, пов'язаних з антинейтрофільними цитоплазматичними антитілами (АНЦА). Хоч МПА є рідкісним АНЦА-асоційованим васкулітом (ААВ), реальна клінічна практика доводить, що захворювання досить поширене явище в нефрологічній практиці, оскільки є системним слабоімунним васкулітом клубочкових капілярів, що призводить до некритичного гломерулонефриту (ГН), який діагностують майже у 100% пацієнтів з МПА. Особливо актуального значення проблема ААВ взагалі і МПА зокрема набуває у період нової коронавірусної інфекції SARS-CoV-2 через спільні анатомічні території інфекції та запалення. У цьому дослідженні повідомляється про три нових випадки МПА у пацієнтів після перенесеного COVID-19. Аналіз та презентація охоплювали демографічні дані, анамнез пацієнтів щодо супутніх захворювань, хронологію з COVID-19, лабораторні результати під час діагностики МПА та деталі подальшого лікування. Порівняльний аналіз хронологічного перебігу МПА в задокументованих клінічних випадках виявляє поліморфність ранніх клінічних проявів, а також різноманітні закономірності прогресування захворювання в розгорнутій стадії. Крім того, ми надаємо короткий огляд літератури щодо діагностичних проблем та патогенетичних механізмів, що лежать в основі взаємозв'язку між інфекцією SARS-CoV-2 і ААВ, а також особливостей клінічних проявів на ранніх і пізніх стадіях МПА.

**Ключові слова:** мікроскопічний поліангіїт, COVID-19, швидкопрогресуючий гломерулонефрит, клінічна картина.

**Introduction.** Microscopic polyangiitis (MPA), granulomatosis with polyangiitis (GPA, in the past Wegener's granulomatosis), and eosinophilic granulomatosis with polyangiitis (EGPA, in the past Churg-Strauss syndrome) are united in the group of vasculitis associated with antineutrophil cytoplasmic antibodies (ANCA) and termed the Anti-neutrophil Cytoplasmic Antibody (ANCA)-Associated Vasculitis (AAVs). This classification was first formulated in the revised nomenclature of vasculitis by the Chapel Hill International Consensus Conference (CHCC) in 2012. [1, 2]. AAVs are a systemic inflammatory autoimmune disease that predominantly affects small vessels and, to a lesser extent, medium-caliber vessels and has a variety of clinical manifestations depending on the affected organs [3]. CHCC 2012 [2] defines AAV as myeloperoxidase-ANCA (MPO-ANCA) or proteinase 3-ANCA (PR3-ANCA)-associated necrotizing vasculitis with little or no immune deposits, predominantly involving small vessels. AAVs have high morbidity and mortality [4] and are one of the most difficult types of vasculitis to treat.

Renal dysfunction is a common and often severe complication of AAVs and the most important predictor of mortality [5]. It is diagnosed in approximately 70% of patients with GPA and almost 100% of patients

with MPA [6-8], often leading to end-stage renal failure (RF) and increased mortality [7, 8].

In 1994, the Chapel Hill Consensus Conference (CHCC) coined the term microscopic polyangiitis to mean weakly immune (ie, little or no immune deposits) necrotizing vasculitis affecting small vessels with or without the involvement of medium-sized arteries [9]. MPA is characterized by the rapid progression of glomerulonephritis (GN) and pulmonary capillaritis with the absence of immune complex deposition on immunofluorescence [10]. According to the 2012 CHCC classification revision, MPA was described as a mild immune vasculitis of small vessels (ie, capillaries, venules, or arterioles) in the absence of granulomas or eosinophilia associated with myeloperoxidase (MPO-ANCA) [1].

During the last three years, the special attention of the global medical community is related to the coronavirus disease 2019 (COVID-19), which is caused by the novel coronavirus infection SARS-CoV-2. Due to the peculiarities of biological properties, this type of virus has a multi-organ tropism of damage. Thus, the disease COVID-19 is a multisystem inflammatory disorder that can lead to endothelial damage, increased risk of thromboembolism, cytokine storm, and autoimmune phenomena [3].

Recently, the scientific literature has been increasing in the number of reports on the potential connection between SARS-CoV-2 infection and AAVs because: first, lung lesions in COVID-19 can mimic the changes observed in patients with AAVs [3, 11-13]; secondly, two diseases can occur together; third,

Ярмола Тетяна Іванівна  
tyarmola@gmail.com

COVID-19 can cause AAV [11, 12]. Diagnosis of new-onset ANCA vasculitis can be challenging in patients with COVID-19, as some symptoms and clinical manifestations of both diseases are common [12].

The rarity of AAVs in general and MPA in particular, which are little known to a wide range of practicing doctors, the increase in the number of new cases during the COVID-19 pandemic, systemic manifestations, a huge number of clinical masks, the difficulty of early diagnosis and management of these patients, determine the practical relevance of this problem in real-life clinical practice.

**The objective** of this study was to examine the characteristics of the clinical progression of early and advanced stages of MPA in patients who previously experienced COVID-19. Additionally, we aimed to assess the changes in laboratory and instrumental indicators among patients with rapid progression of renal failure. To achieve this, we have presented three clinical cases for analysis.

The study applied the new 2022 ACR/EULAR classification criteria for three clinical phenotypes of AAVs: for patients with MPA, GPA, and EGPA [14-16]. It is generally accepted that classification and diagnostic criteria are used to conclude the presence of a certain category of disease in a specific patient [2].

The diagnosis of MPA was substantiated according to the 2022 ACR/EULAR MPA classification criteria, which are now validated for use in clinical trials. These criteria consist of one clinical, three laboratory, one histological, and one radiological criterion, respectively. It should be noted that in the new criteria, the highest score was assigned to MPO-ANCA (or perinuclear ANCA, pANCA). The sum of points is evaluated by 6 points if there are any. A total score  $\geq 5$  allows the classification of MPA [14].

The 2022 ACR/EULAR classification criteria for different clinical and immunological forms of AAVs were applied to all 3 patients treated at the Nephrology and Dialysis Center of «Poltava Regional Clinical Hospital (PRCH) named after M. Sklifosovsky of the Poltava Regional Council». Taking into account the requirements for their use, other syndrome-like diseases that can mimic MPA were primarily excluded: systemic diseases of connective tissue, paraneoplastic nephropathy, multiple myeloma, a number of infectious diseases, other AAVs or other systemic vasculitis, side effects of drugs, etc. [14-16]. For this purpose, all patients underwent a comprehensive examination.

All patients had positive antibodies to myeloperoxidase (anti-MPO), which were, respectively, 166,36 – 81,45 – 160,29 Units/ml (normal  $< 20$  Units/ml). Non-specific markers of inflammation, including leukocytosis, elevated erythrocyte sedimentation rate, elevated CRP, and normocytic anemia are indicative but not diagnostic of MPA disease.

The study of such parameters as the level of serum ferritin and blood transferrin (or the total iron-binding capacity of the blood serum (TIBC)) and their assess-

ment made it possible to carry out differential diagnoses of anemias. In particular, the norm or increase in the level of ferritin (norm: 12-150  $\mu\text{g/l}$  or  $\text{ng/ml}$  for women and, accordingly, 15-150  $\text{ng/ml}$  for men) and the norm or decrease in the level of serum transferrin (or TIBC, norm – 1.7- 4.7  $\text{mg/l}$  or 30.6-84.6  $\mu\text{mol/l}$ , respectively) are important differential diagnostic signs of anemia in a chronic patient when compared with iron deficiency anemia.

### Presentation of clinical cases.

#### Case 1.

Woman O., born in 1974, on June 3, 2022, was hospitalized in the nephrology and dialysis center of the PRCH named after N. Sklifosovsky with complaints of shortness of breath with minor physical exertion, edema on the face, lower legs (more in the morning), blood pressure increase to 200/100 mm Hg., unpleasant taste in the mouth, weight loss of 5-6 kg over the last six months, periodic increase in temperature up to 37,0-37,5°C, general weakness. She denies a history of kidney and lung diseases, however, during the last 4-5 months, she notes an increase in blood pressure.

She considers herself sick for about six months, when one month after the mild form (according to the patient) of the disease of COVID-19, shortness of breath appeared during slight physical exertion, and pains in the heart region began to bother her periodically, after 1.5 – 2 months. BP increased to 200/100 mm Hg. She was treated on an outpatient basis by a family doctor and a cardiologist at her place of residence. In connection with constantly increasing shortness of breath and discomfort in the area of the heart, she was consulted by a cardiac surgeon – no cardiac pathology was detected, and a comprehensive examination was recommended. During this, on 05/27/22, the biochemical blood analysis revealed an increase in serum creatinine level to 976  $\mu\text{mol/l}$ , urea – 30.7  $\text{mmol/l}$ ; in the general blood test – leukocytosis ( $12.2 \cdot 10^9/\text{l}$ ), ESR – 53  $\text{mm/h}$ . Abdominal ultrasound revealed signs of nephritis and left-sided hydrothorax. In connection with this, the patient was hospitalized at the Nephrology and Dialysis Center of PRCH for further examination and treatment.

Among the pathological changes during an objective examination: the patient's condition is severe due to uremic intoxication. Swelling of the feet and lower legs. During the physical examination, the dullness of the percussion sound on the left and the absence of breathing in this area against the background of hard breathing over the entire surface of the lungs. Displacement of the left border of cardiac dullness by 1 cm outwards from the left midclavicular line.

Dynamics of laboratory indicators during 17 days of examination and treatment: general blood test – anemia ( $\text{Hb}=61-86-92-102 \text{ g/l}$ ), acceleration of ESR (45–54–45–46  $\text{mm/h}$ ); biochemical blood analysis – the tendency to hypoproteinemia (59–61.9–56.2–61.1  $\text{g/l}$ ), hypoalbuminemia (34.7–32.2–33.8  $\text{g/l}$ ), signs of hyperazotemia – creatinine (1153.0–1200–1263.0–957.1  $\mu\text{mol/l}$ ), urea (40.5–44.4–40.2–36.2  $\text{mmol/l}$ ), hyperuricemia

(uric acid: 567.3–499.7–411.8  $\mu\text{mol/l}$ ), hypercholesterolemia (total cholesterol: 7.2–8.13–9.18  $\text{mmol/l}$ ), hypocalcemia ( $\text{Ca}=1.03\text{--}1.18$   $\text{mmol/l}$ ), elevated ferritin level (194.6  $\text{ng/ml}$  for the norm of 12–150  $\text{ng/ml}$  for women), the normal level of serum transferrin – 2.02  $\text{g/l}$  (the norm is 1.7–4.7  $\text{mg/l}$ ). Blood glucose – 6,2  $\text{mmol/l}$ , triglycerides – 3.63, HDL – 0.91, LDL – 5.62  $\text{mmol/l}$ . Glomerular filtration rate (GFR) according to the SKD-EPI formula: 3  $\text{ml/min/1.73m}^2$ .

General analysis of urine before establishing the diagnosis and starting treatment without significant dynamics: specific gravity 1005–1010, protein – 8.5–1.16–1.16  $\text{g/l}$ , occasional glucosuria, constant erythrocyturia, moderate leukocyturia – from 3–4 to 18–20 in the field of vision, epithelium – few, cylinders (hyaline 0–3, granular – 3–4 in the field of vision). Urine analysis according to Nechiporenko: marked erythrocyturia. Urinalysis according to Zimnitskyi: specific gravity – 1007–1010, nocturia. Daily proteinuria: diuresis 1.0  $\text{l/day}$ , protein – 1.78  $\text{g/day}$ .

The R $\ddot{o}$ -gram of the chest organs and to confirm the MSCT of the chest organs, ECG and echocardiographic examination (EchoKS), ultrasound of the abdominal cavity, kidneys, and thyroid gland, FEGDS were made. Negative markers of chronic hepatitis (HBV, HCV), and HIV infection. A rapid test for COVID-19 was negative. A sternal puncture was performed – no data on hematopoietic pathology, including multiple myeloma, were found. The patient was examined by related specialists: a rheumatologist, cardiologist, hematologist, neuropathologist, gynecologist, and gastroenterologist. All conclusions are included in the clinical diagnosis.

Considering the first detected rapidly progressive glomerulonephritis (RPGN) with end-stage renal failure, progressive anemia, and signs of systemic damage; absence of chronic diseases in the anamnesis, the ineffectiveness of the therapy, the patient was examined for the presence of systemic diseases and systemic vasculitis. Immunological blood tests from June 8, 2022: Myeloperoxidase (MPO), Ig G antibodies (IFA method, ELISA) – 166,36 Units/ml (normal < 20 Units/ml); Proteinase 3 (PR3), Ig G antibodies (IFA method, ELISA) – < 2 Units/ml (negative result, norm < 20 Units/ml); Double-stranded DNA (ds DNA), Ig G antibodies (fluoroenzymatic method, ELIA) – < 0,5 IU/ml (negative result, norm < 10,0 IU/ml); Antinuclear antibodies (ANA, IFT method) – 1:100 (normal < 1:100); ANA. SmDP-S, Ig G antibodies (fluoroenzymatic method, ELIA) – < 0,7 U/ml (negative result, norm < 7,0 U/ml). Thus, the results of the study can be interpreted as verified systemic ANCA (MPO +) vasculitis.

*A clinical diagnosis was established:* Systemic vasculitis, ANCA-associated vasculitis: microscopic polyangiitis (MPO+), subacute with kidney damage (CKD V (GFR according to the SKD-EPI formula 3  $\text{ml/min/1.73m}^2$ ), prolonged by peritoneal dialysis from 06/09/2022: rapidly progressive glomerulonephritis, urinary syndrome, arterial hypertension II stage, 3rd degree, very high risk); lungs (pneumonitis, PI 0 st.); of

the heart (secondary cardiomyopathy, HF I, FC II with preserved LVEF (EF – 61%, EchoCS from 05.25.22). Anemia of a chronic patient, severe. Congestive gastroduodenopathy. Small nodular leiomyoma of the uterus.

In connection with the patient's refusal of programmed hemodialysis, the patient started peritoneal dialysis sessions. Intensive detoxification, membrane-stabilizing, anti-anemic, hypotensive, and pathogenetic immunosuppressive therapy was carried out (methylprednisolone 24  $\text{mg/day}$  and endoxan (cyclophosphamide) 500  $\text{mg}$  intravenously once every 2 weeks in 200  $\text{ml}$  of 0.9% solution of sodium chloride No. 4, mesna solution during endoxan infusion and 4 hours and 8 hours after infusion. The patient with significant improvement was discharged for outpatient treatment with peritoneal dialysis in combination with conservative therapy under the supervision of an interprofessional team of specialists (family doctor, nephrologist, rheumatologist). The results of the control examination showed an improvement in blood parameters against the background of the therapy. Control immunological examination from 06.10.2022: MPO, Ig G antibodies (IFA, ELISA) – 17.72 Units/ml (negative result, norm < 20 Units/ml);

#### Case 2.

Woman K., born in 1966, on May 24, 2022, was admitted to the Nephrology and Dialysis Center of PSCH with complaints of aching pain in the lumbar region on both sides, swelling of the legs, pain in the muscles of the lower legs, general weakness, shortness of breath when walking less than 100 meters, temperature rise to 38–39°C, weight loss up to 10  $\text{kg}$  over the last 5 months, severe general weakness.

From the anamnesis: she denies kidney disease, but for more than 10 years she has noted an increase in blood pressure, in connection with which she took liprazide at 10  $\text{mg/day}$ . According to the data of the outpatient card during preventive examinations in 2020–2021, urine tests are normal, and creatinine and urea values are within the reference values. Since December 2021, she has noted a gradual deterioration of her well-being, when, during her COVID-associated pneumonia (method of verification of COVID-19 – PCR), she developed shortness of breath during physical exertion, muscle pain, weakness, and began to lose weight. The condition critically worsened at the end of March 2022, when a debilitating subfebrile temperature joined, and weakness increased (during the blood serum creatinine examination – 64  $\mu\text{mol/l}$ ). In April 2022, she was treated in the therapeutic department of the Central Hospital, where for the first time an increase in creatinine up to 149  $\mu\text{mol/l}$  (28.04.2022) was detected, and in the general analysis of urine for the first time, proteinuria was detected – 0.8  $\text{g/l}$ , erythrocyturia (40–50 in the field of vision). Antibacterial therapy had no effect. In connection with a severe headache, high blood pressure, muscle pain, and pronounced cerebral symptoms, she was treated in the neurological department of the Central Hospital, where the creatinine level was already

366  $\mu\text{mol/l}$ . In the last week, a fever of up to 38–39°C was observed. For further examination and treatment, the patient was referred to a nephrologist for consultation and hospitalized at the Nephrology and Dialysis Center of PRCH. During her stay in the hospital, on 06/07/2022 and 06/08/2022, the patient had a cough with streaks of blood (episodes of hemoptysis).

Evaluating the objective condition of the patient as of medium severity, it should be noted that three days after the start of treatment, a hemorrhagic rash appeared on the lower legs (palpable purpura). Swelling of the feet and lower legs. During the physical examination: percussion over the lungs there is a clear lung sound, during auscultation – breathing is hard, and there are no wheezes. The limits of relative cardiac dullness are shifted to the right by 1 cm from the right edge of the sternum in the 4th intercostal space, and the left by 1.5 cm outward from the left midclavicular line in the 5th intercostal space. Cardiac activity is normal, tones are rhythmic, weakened, systolic murmur at the apex and Botkin's point, the emphasis of the II tones on the aorta. Liver: with percussion, the lower edge is 1 cm below the edge of the costal arch. The spleen is enlarged, and the lower pole is palpable. The tapping symptom is weakly positive on both sides. Urination is not disturbed. Daily diuresis was 1.5 l.

The dynamics of changes in blood parameters during a month of hospitalization: in the general blood test – anemia (Hb= 57–78–77–74 g/l), leukocytosis (11.7–15.68–14.09–8.83 ( $\times 10^9/\text{l}$ )), moderate thrombocytopenia (100.0–185.0–218.0–191.0 ( $\times 10^9/\text{l}$ )), ESR acceleration (70–67–36–16 mm/h). In the biochemical blood analysis – total protein 63.1–65.1–65.3–60.7 g/l, hypoalbuminemia (30.0–35.6–34.7 g/l), hyperazotemia: creatinine (461.3–641.6–408.0–245.0  $\mu\text{mol/l}$ ), urea (26.7–35.2–33.1–21.1 mmol/l); hyperuricemia (uric acid 656.3–843.6–587.3–548.8  $\mu\text{mol/l}$ ), hypocalcemia (Ca=1.21–1.25 mmol/l): hypomagnesemia (Mg=0,6 mmol/l); total cholesterol (3.8–4.26–4.88–6.06 mmol/l), hyperfibrinogenemia (4.5 g/l). CRP from 96 to 192 mg/ml (normal up to 10,0 mg/l). Blood glucose – 4.5 mmol/l, glycated hemoglobin – 5.3%. Blood culture for sterility (25.05.22): no aerobic bacterial flora was detected. Procalcitonin (26.05.22): 1.154 ng/ml (normal – less than 0,05 ng/ml). GFR according to the SKD-EPI formula: 9 ml/min/1.73m<sup>2</sup>.

General analysis of urine – specific gravity 1007–1020, protein – 0.18–1.05 g/l, erythrocytes – from 2–4 in the field of vision up to 1/2 field of vision, leukocytes – from 2–3 in the field of vision up to 1/4 in field of vision, epithelium – few, cylinders – 0. Urine analysis according to Nechiporenko: leukocytes – 2500, erythrocytes – 3500, cylinders – 0. Urinalysis according to Zimnitskyi: specific gravity – 1007 – 1010, nocturia. Daily proteinuria: diuresis – 1.0 l/day, protein – 1.47 g/day.

The patient was examined for markers of chronic hepatitis (HBV, HCV), HIV infection – the indicators were negative.

On May 26, 2022, an immunological blood test was performed to exclude syndrome-like diseases (mimic disease): blood test for MPO, Ig G antibodies (IFA, ELISA method) – 81.45 Units/ml (norm < 20 Units/ml); PR3, Ig G antibodies (IFA method, ELISA) – < 3 U/ml (negative result, norm < 20 U/ml), ANA, double-helical DNA (dsDNA), IgG antibodies: 1.2 IU/ml (negative result, norm < 10,0 IU/ml); antinuclear antibodies (ANA, IFT method): 1:100 (normal < 1:100). Therefore, the results of the study can be interpreted as verified systemic ANCA (MPO +) vasculitis.

On the ECG: diffuse violation of the repolarization of the left ventricular myocardium.

Ultrasound of abdominal organs demonstrated a moderate increase in echogenicity of kidney parenchyma. Enlargement of the spleen. On May 27, 2022, a sternal puncture was performed. Data for hematopoiesis pathology, including multiple myeloma, were not found. An intestinal examination was conducted and inflammatory and malignant diseases were excluded.

On the X-ray of the chest organs (May 30, 2022) in the front projection (compared to the image dated March 16, 2022), liquid thickening and deformation of the pattern remained in the lower-medial sections of the right lung. Darkening of the lower parts of the lungs on the left. Pronounced deformation (scoliosis) of the spine. Cor – expanded in the transverse dimension.

On May 31, 2022, a clinical conference was held with the involvement of related specialists (rheumatologist, hematologist, pulmonologist, neurologist, gastroenterologist, and oncologist): taking into account the rapid increase in uremic intoxication due to rapidly progressing nephritis, signs of acute kidney injury (AKI), the patient was prescribed acute hemodialysis treatment with 01.06.2022

On the control X-ray from 06.06.22. (compared to the X-ray from 05/30/22) – negative dynamics on the right – subtotal heterogeneous lesion of the lung tissue with infiltrative changes against the background of an increased and thickened lung pattern. On the left, the area of thickening and deformation of the lung pattern in the lower medial sections, the sinuses are free. Cor – expanded in the transverse dimension. Scoliosis of the spine. Conclusion: it is necessary to differentiate polysegmental pneumonia and lung damage due to the underlying disease. MSCT of the chest organs (06.06.22): CT signs of infiltrative changes in both lungs, more on the right, probably on the background of the underlying disease; degenerative-dystrophic changes of the thoracic spine.

Analysis of sputum (06.08.22): red, mucous, pathological impurities – blood, erythrocytes – in the entire field of vision, leukocytes 0–2 in the field of vision, macrophages – rarely, MBT was not detected.

*Clinical diagnosis.* Systemic vasculitis, ANCA-associated vasculitis: microscopic polyangiitis (MPO+), subacute with kidney damage (CKDV (GFR according to the SKD-EPI formula 9 ml/min./1,73m<sup>2</sup>): rapidly progressive glomerulonephritis, urinary syndrome. The

acute kidney damage of the 3rd degree, restoration of diuresis (acute hemodialysis sessions from 06/1/2022 to 06/20/2022. Arterial hypertension of the 2nd degree, 2nd stage, the risk is very high); lung damage (pneumonitis, hemoptysis, respiratory failure of the 2nd stage); musculoskeletal system (polyarthritides, myalgia); peripheral nervous system (polyneuropathy); skin (purpura); Gastrointestinal tract (erosive gastritis, GERD with erosive esophagitis, stage C.) Anemia of mixed genesis, severe degree. Secondary thrombocytopenia of a mild degree. Secondary encephalopolyneuropathy with tetraparesis with an emphasis in the legs, myopathic syndrome, persistent severe senestopathic syndrome.

The patient received pathogenetic therapy: glucocorticosteroids (medrol 48 mg in the morning and 16 mg in the afternoon after meals), endoxan (cyclophosphamide) 500 mg intravenously once every 2 weeks in 200 ml of 0.9% solution of sodium chloride No. 4, mesna solution under the time of endoxan infusion and 4 hours and 8 hours after infusion, detoxification, hypotensive, hemostatic, antianemic, anticoagulant therapy, antisecretory agents, cytoprotectors, prokinetics, calcium and vitamin D3 preparations.

During inpatient treatment, 8 sessions of acute hemodialysis were performed, and the general condition of the patient significantly improved (creatinine level decreased to 245.0  $\mu\text{mol/l}$ , and urea to 21.1 mmol/l, diuresis was fully restored), which made it possible to stop dialysis sessions. At the end of the inpatient treatment, positive dynamics of the main blood parameters were noted. The patient is currently undergoing pathogenetic therapy.

### Case 3.

Patient H., born in 1975, from 10/31/2022 to 11/24/2022 was undergoing further examination and treatment at the Nephrology and Dialysis Center of PSCH. During hospitalization, he complained of headaches, hand tremors, and general weakness. From the anamnesis: he denies kidney disease. For some time he worked at an enterprise with harmful production conditions (a shoe factory). According to the patient, he considers himself sick since the beginning of June 2022, when the temperature rose to 39,3-39,5°C, and first noticed the red color of urine and the appearance of coughing up blood during coughing. During the examination, COVID-19 was diagnosed (verification method – PCR).

After 2 weeks, his health worsened: shortness of breath, and severe weakness appeared, and after another week – dizziness, a decrease in the amount of urine, because of which he consulted a family doctor. During the examination, anemia was detected, in connection with which anti-anemic therapy was prescribed. There were no positive dynamics from the treatment. During the examination on June 21, 2022, an increase in the level of creatinine to 270  $\mu\text{mol/l}$  and urea to 9.25 mmol/l was detected for the first time. Control of renal indicators on July 25, 2022: creatinine – 334  $\mu\text{mol/l}$ , urea – 41 mmol/l, and in the general analysis of urine,

proteinuria within the range of 1.0 g/l was detected. On July 26, 2022, a chest X-ray showed bilateral interstitial pneumonitis. 07/27/2022 – consulted by an endocrinologist, diagnosed: idiopathic hypothyroidism, first detected, stage of decompensation. Autoimmune thyroiditis. Prescribed L-thyroxine, Erbisol. During ultrasound of the abdominal organs and kidneys, the kidneys are lumpy, the parenchyma is preserved, and there are kidney cysts. He notes a constant increase in blood pressure. On August 1, 2022, he was consulted by a hematologist and a nephrologist. Diagnosis: anemia of a chronic disease of mild degree. The nephrologist's preliminary diagnosis is CKD IV: pyelonephritis, kidney cysts, arterial hypertension, secondary anemia, and hypercholesterolemia. 26.08.2022 p. in the biochemical blood analysis: creatinine – 524  $\mu\text{mol/l}$ , urea – 20.7 mmol/l, CRP – 18.1 mg/l (normal up to 10.0 mg/l), seromucoids – 6.9 Units (normal 0, 12-0.2 Units), D-dimer – 1.23  $\mu\text{g/ml}$  (normal up to 0.5  $\mu\text{g/ml}$ ). On the same day, he was consulted by a pulmonologist. Diagnosis: COPD, group A, pulmonary insufficiency, stage I, arterial hypertension, CKD. He received treatment on an outpatient basis, but without progress, so he was sent to inpatient treatment, where he stayed for two weeks at the beginning of September. A diagnosis was made: systemic inflammatory response syndrome (post-inflammatory). CKD IV: glomerulopathy, urinary syndrome. Arterial hypertension II stage, 2 degree, and high risk. Autoimmune thyroiditis, idiopathic hypothyroidism, first detected, stage of decompensation; Anemia of chronic disease. Bilateral pneumonitis PI 0. From 30.09.2022 to 07.10.2022, he was receiving inpatient treatment in the city of Kremenchuk (creatinine – 503 – 376  $\mu\text{mol/l}$ ). During the treatment, the patient was prescribed Medrol 16 mg per day. In connection with a stable serious condition, the patient was sent for consultation to a nephrologist of the PSCH, who referred him to the hospital for further examination and treatment.

Objectively: the general condition is severe. A hemorrhagic rash that has changed in color on the skin of the body. Percussion over the lungs has a clear lung sound, during auscultation, breathing is hard, especially in the lower parts, and there are no wheezes. Pulse 84 bpm. rhythmic, satisfying properties. Blood pressure 140/90 mm Hg. Art. Edges of relative cardiac dullness: right – 1.5 cm from the right edge of the sternum in the 4th intercostal space, the left is shifted 0.5 cm outward from the midclavicular line in the 5th intercostal space. Cardiac activity is normal, tones are muffled, systolic murmur at the apex and Botkin's point, the emphasis of the second tone on the aorta. The abdomen is soft and painless on palpation. The liver protrudes 2 cm from under the edge of the costal arch. The spleen is not palpable. Tapping symptom is negative on both sides. There are no swellings. Daily diuresis is about 2.1 liters.

Dynamics of changes in blood parameters during 25 days of hospital stay: in the general blood test – anemia (Hb=116–117–112–128 g/l), transient leukocyto-

sis (7.8–6.1–15.6–16.4  $\times 10^9/l$ ), increased ESR (12–34–30–27 mm/h); in the biochemical blood analysis: total protein 62.0 g/l, hypoalbuminemia (37.0 g/l), hyperazotemia: creatinine (430.3–359.9–363.2–411.1–360.7–486, 1  $\mu\text{mol/l}$ ), urea (23.0–16.4–10.1–29.8–31.4–31.9 mmol/l); hyperuricemia (uric acid 484.0–390.1  $\mu\text{mol/l}$ ), hypocalcemia ( $\text{Ca}=1.16\text{--}1.23$  mmol/l), elevated ferritin level (177.2 ng/ml for the normal range of 15–150 ng/ml for men), reduced level of serum transferrin – 1.64 g/l (normally 1.7–4.7 mg/l).

GFR according to the SKD-EPI formula: 13 ml/min./1.73m<sup>2</sup>.

General analysis of urine – specific gravity 1022, protein – 0.48 g/l, scanty urine sediment, insignificant number of bacteria. Urine analysis according to Nechiporenko: leukocytes – 5750, erythrocytes – 11250, cylinders – 90 in 1 ml. Daily proteinuria: diuresis – 2.2 – 2.5 l/day, protein – 1.66 – 3.52 g/day.

The patient was examined for markers of chronic hepatitis (HBV, HCV), HIV infection – the results were negative.

On November 9, 2022, an immunological blood test was performed to exclude syndrome-like diseases: blood test for MPO, IgG antibodies: 160.29 Units/ml (normal < 20 Units/ml, the result is positive). PR3, Ig G antibodies (IFA method, ELISA) – < 2 Units/ml (negative result, norm < 20 Units/ml). Goodpasture's syndrome was ruled out in our patient by a negative test for antibodies to the glomerular basement membrane: anti-GBM glomerular basement membrane antibody – 0.3 U/ml (<7.00 – negative). Thus, the results of the study can be interpreted as verified systemic ANCA (MPO +) vasculitis.

Rö-gram and MSCT of the thoracic organs, ECG and echocardiography, ultrasound of the abdominal cavity, kidneys, and thyroid gland, FEGDS were made. The patient was examined by related specialists: a rheumatologist, cardiologist, pulmonologist, gastroenterologist, neurologist, urologist, ENT (the findings were included in the clinical diagnosis).

*Clinical diagnosis.* Systemic vasculitis, ANCA-associated vasculitis: microscopic polyangiitis (MPO+), acute with kidney damage (CKD V (GFR according to the SKD-EPI formula 13 ml/min./1.73m<sup>2</sup>): rapidly progressive glomerulonephritis, urinary syndrome. Arterial hypertension II stage, degree 1, high risk), lung (pneumonitis, PI 0, history of hemoptysis); heart (secondary cardiomyopathy, CHF I, FC II). Anemia of a chronic patient, mild. Chronic gastroduodenitis, stage of moderate exacerbation. Chronic pancreatitis, stage of remission. Chronic cholecystitis, stage of remission. Non-alcoholic steatohepatitis. Right kidney cyst. Chronic prostatitis, stage of remission.

Pathogenetic therapy was started: pulse therapy with Sol-Medrol 500 mg was performed for three days, from 11/19/2022 – Medrol tablets 60 mg per day. R-n Endoxan 500 mg intravenously No. 1 (November 18, 2022). The patient was discharged from the department due to the high incidence of viral diseases, including

Covid-19, in the center of nephrology and dialysis. He was hospitalized for the 2nd course of pulse therapy with endoxan on December 1, 2022, which was never completed.

Upon re-hospitalization, he complained of pronounced general weakness, shortness of breath when walking less than 100 m, an increase in blood pressure to 200/100 mm Hg, severe swelling of the legs, and an increase in body temperature to 38.0°C. According to the patient, during his stay at home, the temperature rose, shortness of breath, and swelling gradually increased, which the patient associated with ARVI.

Objectively: the general condition is difficult. The skin and visible mucous membranes are pale. Swelling of feet, legs, thighs, and face. On auscultation, there are small bubbling rales in the lungs on the left in the lower parts. Limits of relative cardiac dullness: right 1.5 cm from the right edge of the sternum in the IV intercostal space, left 1.5 cm outward from the midclavicular line in the V intercostal space. Cardiac activity is normal, tones are weakened. Blood pressure 180/90 mm Hg, pulse 84 bpm. rhythmic, satisfactory properties. The abdomen during palpation is soft, painless, and enlarged due to ascites. Liver: the lower edge protrudes from under the costal arch, painful on palpation. The spleen is not palpable. Tapping symptom is negative on both sides. Diuresis is less than 500 ml.

The dynamics of changes in blood parameters during the 7-day stay in the hospital: in the general blood test – anemia (Hb=102–65–84–100 g/l), leukocytosis with the transition to leukopenia (23.9–9.5–8.1–3.3 ( $\times 10^9/l$ )), moderate thrombocytopenia with the transition to severe (86.0–58.0–44.0–9.0 ( $\times 10^9/l$ )), acceleration of ESR (43–45–30–25 mm/hour); in the biochemical blood analysis – total protein 53.6–47.2–48.9 g/l, hypoalbuminemia (27.0–24.0–25.7 g/l), hyperazotemia (creatinine 708.5–687.0 (after acute hemodialysis 654.7)–791.5–724.1–661.1–727.1  $\mu\text{mol/l}$ , urea 68.8–52.5–49.8–52.5–57.4–31.9 mmol/l); hyperuricemia (uric acid 690.4–656.8–632.9  $\mu\text{mol/l}$ ), hypocalcemia ( $\text{Ca}=1.10\text{--}1.23$  mmol/l), hyperkalemia ( $\text{K}=7.1$  mmol/l), and hyponatremia ( $\text{Na}=132.2\text{--}127.0$  mmol/l). Blood glucose – 26.0–18.5 mmol/l. Procalcitonin (PCT) – 100.0 ng/ml (the norm is less than 0.05 ng/ml). Blood was taken three times for culture.

MSCT of the chest and abdominal organs (December 6, 2022): CT signs of right-sided pneumohydrothorax. Focal-infiltrative changes in the lungs are determined bilaterally, mainly in S4, and S5 of the right lung, the area of consolidation with destructive changes. Local limited fluid accumulation on the front sheet of the renal fascia.

On 02.12.2022, a consultation was held with the participation of related specialists and, taking into account the patient's serious condition, increasing uremic intoxication, anemia, edematous syndrome, the ineffectiveness of conservative therapy, the patient was shown the placement of 2-luminal catheters and acute

dialysis sessions. Reduction of GCS dose by 4 mg daily. Insulin therapy is prescribed for newly diagnosed type II diabetes.

In connection with the loss of consciousness on 07.12.2022, an on-duty neurologist was urgently called to the patient. At the time of the patient's examination, an acute violation of cerebral blood circulation cannot be ruled out. At 8:35 a.m., the patient's condition worsened sharply: blood pressure 40/0 mmHg, thready pulse on the carotid arteries. Resuscitation measures and medical therapy were immediately started. A resuscitation team was urgently called, which continued resuscitation measures, but without the desired effect. At 9.35 biological death was confirmed.

**Final diagnosis.** Systemic vasculitis, ANCA-associated vasculitis: microscopic polyangiitis (MPO+), acute with kidney damage (CKDV (GFR according to the SKD-EPI formula 7 ml/min./1.73m<sup>2</sup>): rapidly progressive glomerulonephritis, nephrotic syndrome complicated by acute kidney damage III, acute dialysis sessions (from 2.12.2022), arterial hypertension II stage, degree 1, high risk); lungs (pneumonia, hemoptysis in history); Gastrointestinal tract (abdominal ischemic syndrome). Secondary anemia is moderately pronounced and severe thrombocytopenia. Type 2 diabetes mellitus, newly diagnosed. Chronic pancreatitis, stage of exacerbation. Chronic gastroduodenitis, stage of exacerbation. Acute violation of cerebral blood circulation, cerebral edema. Bilateral polysegmental congestive pneumonia with S4-S5 destruction of the right lung, severe course, clinical group III, complicated by bilateral hydrothorax of a small volume and bilateral pneumothorax of a small volume, respiratory insufficiency II-III. Sepsis. Paraneuritis, right kidney abscess. Multiple organ failure syndrome. Condition after resuscitation measures.

At the autopsy microscopically, thickening is found in individual glomeruli glomerular basement membrane with total glomerulitis (Fig. 1).

A significant number of glomeruli with proliferative changes in the vascular pedicle with its thickening and the formation of segmental sclerosis in the form of nodular structures (Fig. 2).

However, most glomeruli are collapsed due to extracapillary proliferation in the form of crescents with the formation of fibrocellular and fibrous structures (Fig. 3).

Epithelium of renal tubules with dystrophic changes, focally desquamated. Protein masses with single leukocytes are noted in the lumen of the renal tubules. Lymphohistiocytic infiltration with a small number of neutrophils is noted in the kidney interstitium.

The results of the generalized analysis of the features of the clinical course of MPA after COVID-19 in the 3 presented clinical cases are presented in Table 1.

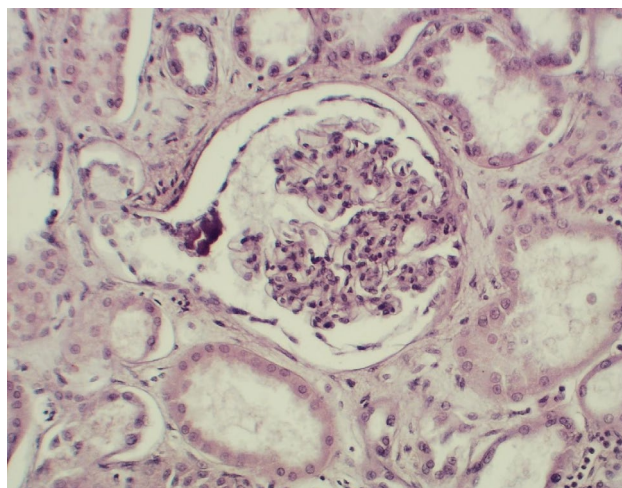


Fig. 1. Microscopic examination of the kidney of the deceased G.: thickening of the basal membrane of the glomerulus with total glomerulitis. Hematoxylin and eosin stain, x100.

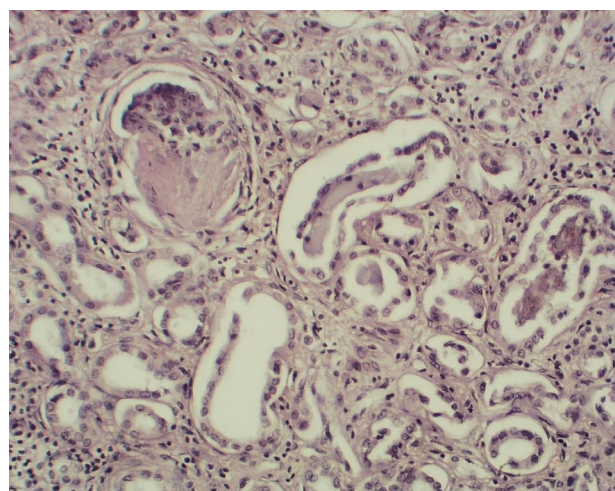


Fig. 2. Microscopic examination of the kidney tissue of the deceased G.: proliferative changes in the vascular pedicle of the glomeruli with the formation of segmental sclerosis. Hematoxylin and eosin stain, x100.

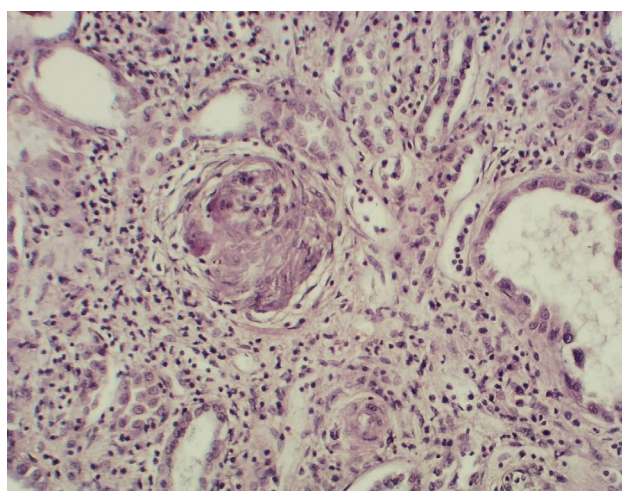


Fig. 3. Microscopic examination of the kidney tissue of the deceased G.: extracapillary proliferation in the form of crescents with the formation of fibrocellular and fibrous structures. Hematoxylin and eosin stain, x100.

Table 1

**Brief description of demographic indicators and analysis of clinical and laboratory data in 3 patients with newly diagnosed MPA after suffering from COVID-19**

Signs	Case 1	Case 2	Case 3
Age, years	47	56	46
Sex	female	female	male
Course	Subacute	Subacute	Acute
Associated diseases	-	Arterial hypertension over 10 years	AIT, hypothyroidism.
Peculiarities of history	Outpatient treatment at a family doctor and cardiologist	Inpatient treatment in therapeutic and neurological departments	Outpatient treatment without dynamics, twice inpatient treatment
Complaints: symptoms (syndromes) that led to hospitalization	Cardiac syndrome, shortness of breath, edema on the face, legs, blood pressure increase to 200/100 mm Hg., weight loss low fever	muscle syndrome, pain in the lumbar region, swelling of the legs, shortness of breath, febrile to (up to 38.0-39.0°C), weight loss up to 10 kg, neurological symptoms	Headache, hand tremors, general weakness.
Renal history	Denies	Denies	Denies
Temperature	Subfebrile	Moderately febrile	Normal
Blood pressure	High	High	Increased
Weight loss during the period of illness	5-6 kg	10 kg	Absent
Kidney damage	RPGN	RPGN, AKI	RPGN, AKI
Lung damage	The lung pattern is smoothed and deformed due to the mixed component	CT scan shows signs of infiltrative changes in both lungs, more on the right	Bilateral interstitial pneumonitis, after 3 months CT scan shows signs of "ground glass" areas in both lungs
Changes in the pulmonary system	+	+	+++
Hemoptysis	-	+	++
Skin lesions	-	Purpura	Purpura
Gastrointestinal lesions	-	GERD, erosive esophagitis, stage C, erosive gastritis	-
Hepatosplenomegaly	-	+	Hepatomegaly
Anemia / Hb level (g/l): pre-hospital stage – during hospitalization	- 61-102	- 57-78	anemia 116-128
Leukocytes (x10 <sup>9</sup> /l)	7,5 – 11,28	11,7 – 15,7	7,8 – 16,4
Eosinophilia (%)	1	5	0-2
Lymphocytes (%)	10-15	7-28	9-42
ESR (mm/h)	45	70	12
Serum albumin (g/l)	34,7	30,0	37,0

Continuation of Table 1

Signs	Case 1	Case 2	Case 3
sCr level ( $\mu\text{mol/l}$ ): first discovered	936,0	149,0	270,0
hospitalization	1153,0	461,3	430,3
peak level	1263,0	641,6	791,5
at the time of discharge from the hospital	957,1	245,0	486,1
Urea ( $\mu\text{mol/l}$ ):	40,5	26,7	23,0
Daily proteinuria (g/day)	1,78	1,47- 0,148	1,66 – 3,52
General analysis of urine: proteinuria (g/l)	8,5 – 9,6	1,05 – 0,83	0,48
Erythrocyturia according to Nechyporenko-	on $\frac{1}{3}$ of the field of view 20,000 in 1 ml	on $\frac{1}{2}$ field of vision 3,500 in 1 ml	not changed 2-3, changed 3-5, 11, 250 in 1 ml
Serological research, Ig G MPO	anti-MPO-ANCA	anti-MPO-ANCA	anti-MPO-ANCA
Titers of antibodies to MPO (U/ml), norm < 20	166,36	81,45	160,29
Titers of antibodies to PR3 (U/ml), norm < 20	< 2	< 3	< 2
<b>Timeline with Covid-19:</b>			
Date of Covid-19	November – December 2021.	December 2021. covid- pneumonia	June 2022.
Course	mild	severe	severe
The appearance of signs of kidney damage during Covid-19	–	–	Change in the color of urine (red), decrease in its quantity
The first signs/symptoms of worsening health after suffering from Covid-19	After 1 month, the appearance of shortness of breath, cardialgia; in 2 months – blood pressure increase to 200/100 mm Hg.	Gradual worsening at once (myalgia, shortness of breath, weight loss), and significant – after 3 months: low fever, increased shortness of breath, weakness, weight loss	After 2 weeks, shortness of breath, pronounced weakness, and after 3 weeks: dizziness, oliguria, anemia without positive dynamics after treatment
Hyperazotemia was detected for the first time	After 6 months	After 4 months	In 2 weeks
Hospitalization to the center of nephrology and dialysis	After 6 months	After 5 months	After 4 months
Time between Covid-19 and MPA	6 months	5-6 6 months	Simultaneously
Renal replacement therapy	Peritoneal dialysis	Acute hemodialysis	Acute hemodialysis
Result	Improvement	Improvement	Death

Abbreviations: AIT – autoimmune thyroiditis, sCr – blood serum creatinine; RPGN – rapidly progressive glomerulonephritis, AKI – acute kidney damage, anti-MPO-ANCA = anti-myeloperoxidase-ANCA.

**Discussion.** Publications of recent years indicate an increase in the incidence and prevalence of AAVs both worldwide and in individual European countries [4, 8, 17, 18]. This fact is confirmed by the actual clinical practice of the Nephrology and Dialysis Center of PRCH [19].

The problem of AAVs and MPAs is especially relevant during the period of the new SARS-CoV-2 coronavirus infection, as the COVID-19 pandemic continues to change the world [20, 21]. Despite the hope that the COVID-19 pandemic will end in 2022, we are currently witnessing the continuation of the spread of COVID-19 in the world, as evidenced by the rapid increase in the number of infections in December 2022 in China (tens of millions daily and 248 million in the first 20 days December, which is almost 18% of the country's population) [20] and Japan. According to data as of December 30, 2022, the number of deaths from COVID-19 in China has increased to 9,000 per day [21].

According to Allen N and others [22], SARS-CoV-2 infection causes an increase in the level of circulating cytokines and hyperactivation of immune cells, which is called a cytokine storm and leads to a dysregulation of the immune response not only to the pathogen itself but also contributes to cellular and vascular injuries and multiorgan dysfunction. Cytokine-induced endothelial inflammation and vascular pathology of COVID-19 are well described in postmortem biopsies and several case reports of micro/macro thrombotic events in small, medium, and large vessels and vasculitis in multiple organs [22, 23].

During the COVID-19 pandemic, the diagnosis and treatment of AAV have been discussed differently. AAV can mimic COVID-19 in terms of lung involvement, COVID-19 can co-occur with AAV, and COVID-19 can cause AAV-like symptoms [12]. The development of AAV after the transfer of COVID-19 is reported in many clinical reports [3, 11-13, 24-29]. The diagnosis of new ANCA-associated vasculitis can be difficult in the context of severe infection with COVID-19 due to common anatomical areas of infection and inflammation [30].

Because MPA and COVID-19 can affect the lungs and kidneys, it can pose a diagnostic challenge and lead to a delay in diagnosis, potentially worsening patient and kidney outcomes. It is especially important to identify patients who may have developed MPA after COVID-19, which may be masked by a new coronavirus infection.

Today, there is more and more evidence that SARS-CoV-2 is another virus that can lead to disruption of the regulation of the immune system and provoke the appearance or exacerbate already existing autoimmune diseases in children and adults [24-26, 31-35], especially in genetically predisposed individuals [12, 32, 35]. Moreover, numerous new autoimmune diseases in adults have been described in the literature as post-infectious complication of COVID-19 infection [25]. That is why the diagnosis of new cases of the

development of AAVs in a patient with COVID-19 is a problem [12].

As Madanchi and others point out, as of late 2021, more evidence suggests a possible link between COVID-19 and AAV, although causality cannot be proven, it is plausible [13]. As the global spread of COVID-19 continues, there are increasing numbers of new reports of a potential association between infection with COVID-19 and AAVs and the development of vasculitis in patients with COVID-19 infection [3, 12, 13, 24-29]. A systematic review of the literature and own research by Bryant and others [20] and many other foreign scientists indicate that SARS-CoV-2 infection may be another viral trigger for the development of AAVs in children and adults [12, 28, 32, 33] literature search from December 2019.

According to the results of a review of the scientific literature in the PubMed database for the period from the beginning of the COVID-19 pandemic to March 2022, Seyda Ozcan et al. found that 17 reports of 20 cases of AAVs (including their case) were published, which were associated with the disease of COVID-19 [29]. The authors reviewed the available literature and reported that the presence of COVID-19 and AAVs in the same patient may be coincidental, but the presence of similar previous cases may indicate their association. Based on the results of the analysis, the authors determined that in 12 cases, COVID-19 and AAVs were concurrent, and in the remaining eight cases, a duration of 25 days to 6 months was reported [29]. The authors conclude that COVID-19 may trigger cases of vasculitis, especially in patients with predisposing factors.

Thu Aung Z, et al did a similar electronic search in databases MEDLINE, EMBASE, CINAHL and EMCARE for the period from April 2020 to February 2022. Among the 24 cases they found in the literature, 11 patients had AAV diagnosed one to six months after COVID-19, 1 case several weeks later, while 12 cases had both COVID-19 and AAV diagnosed during the same hospitalization. [3].

Liu and co-authors in their publication also draw attention to the existing connection between COVID-19 and autoimmune diseases [34]. The authors report that COVID-19 is similar to autoimmune diseases in terms of clinical manifestations, immune responses, and pathogenic mechanisms. Persistent immune responses are involved in the pathogenesis of both diseases, and autoantibodies as a marker of autoimmune diseases can also be detected in patients with COVID-19.

One of the proposed mechanisms for the development of autoantibodies, including ANCA, in the context of a COVID-19 infection, is the presence of a large infiltration of neutrophils and neutrophil extracellular traps (NETs) in places of immune thrombosis and tissue necrosis, which can contribute to the violation of tissue tolerance with the formation of antibodies [30].

Kronbichler et al. in their review article summarize the similarities in the pathogenesis of COVID-19 and

AAVs, as NETs are induced in both diseases [27]. It has been established that SARS-CoV-2 infection can contribute to the increased formation of NETs, which can cause damage and dysfunction of endothelial cells and further enhance apoptotic cell death [36]. Moreover, high levels of NETs have been found in SARS-CoV-2 infection with severe organ damage and high mortality [37], similar to ANCA-associated vasculitis, in which complement activation and endothelial dysfunction are induced by NETs [38].

Recently was published the article «SARS-CoV-2 Infection: A Forerunner or Precursor in Anti-neutrophil Cytoplasmic Antibody-Associated Vasculitis With Kidney Injury» [3]. The authors note that COVID-19 and AAVs are multisystem diseases. A causal relationship is believed to exist between the two conditions, and this is supported by clinical case reports [12, 22, 25, 27, 29, 35, 39]. Moreover, the symptoms of COVID-19 can mimic those of vasculitis, especially if the respiratory system is affected. That is why early diagnosis and timely treatment of ANCA vasculitis is extremely important, as it reduces the risk of serious organ damage [3].

However, it should be emphasized that only a small number of publications refer to cases of MPA in patients with a new coronavirus infection [22, 39, 40]. Our own clinical experience [19], which demonstrates an increase in the number of patients with MPA, especially after infection with COVID-19, is no exception, which is what we want to share in this publication.

In 2009, the European League Against Rheumatism (EULAR) published guidelines for the treatment of primary systemic vasculitis of small and medium vessels, which included the treatment of AAVs. In 2016, an international interdisciplinary working group of experts published updated recommendations for the diagnosis and treatment of systemic vasculitis with an emphasis on AAVs [41]. This update was made jointly with the European Renal Association – European Dialysis and Transplant Association (ERA-EDTA) and the European Vasculitis Society (EUVAS). The recommendations have gathered modern scientific achievements in the study of AAVs and are based on data from randomized clinical trials, systematic interdisciplinary literature reviews and the opinion of 21 experts from 12 countries in Europe and the USA. The AAVs Specialist Working Group was multidisciplinary and consisted of 21 members representing EULAR and ERA-EDTA: six nephrologists, six rheumatologists, two internists, a pulmonologist, an ophthalmologist, an otorhinolaryngologist, an immunologist, a pathologist, a nurse and one patient with experience and/or clinical knowledge in the field of systemic vasculitis.

AAVs are a highly variable group of diseases that are unpredictable and potentially life-threatening. Relapse is common for AAVs, which can return years after achieving remission, even in previously unaffected organ systems. In addition, AAVs negatively affect the quality of life even in patients who are considered to

be in clinical remission. Long-term follow-up and rapid access to specialized services are essential for all patients with AAVs. At all stages, patients need the involvement of specialists in the field of ANCA-vasculitis: not only a rheumatologist but also doctors of other specialties [41].

Therefore MPA is a rare ANCA-associated necrotizing vasculitis that predominantly affects pulmonary and renal capillaries [42], but small vessels and other organs may also be involved. [7, 10, 42-45]. MPA is characterized by inflammation of small blood vessels, the absence of granulomas on histopathology, and the presence of circulating ANCA [7, 42]. The ANCA test for MPA gives a positive result in 80% of cases. Among these, perinuclear ANCA (p-ANCA) associated with myeloperoxidase (MPO-ANCA) are present in 60%, while cytoplasmic ANCA (c-ANCA), associated with proteinase-3 ANCA (PR3-ANCA), present in 40%. However, a small number of patients are ANCA-negative [7], creating a diagnostic challenge and potential delay in treatment [8]. Atypical ANCAs that are not directed against PR3 or MPO can be found in inflammatory bowel disease, autoimmune disease, and malignancy [5].

During the COVID-19 pandemic, the early diagnosis of MPA remains as challenging for physicians of various specialties as it was before it. This is primarily due to the damage to many organs, the diversity of the clinical picture and variants of the course of the disease, and the blurring and atypicality of clinical manifestations, especially in the debut of the disease, which requires the exclusion of diseases that can mimic MPA [14]. Moreover, the clinical features of MPA cause a diagnostic dilemma due to their non-specific and varied clinical manifestations [42].

MPA is often manifested by a prolonged prodromal phase of typical constitutional symptoms such as fever, general weakness, malaise, anorexia, weight loss, or a complex of uncharacteristic musculoskeletal complaints with myalgias and myositis, arthralgias and arthritis for weeks or months without the involvement of specific organs with further development of RPGN [10, 45]. We observed all these typical initial symptoms in various variations of the combination in the three clinical cases presented by us.

Other initial manifestations of MPA include voiding abnormalities, cough with or without hemoptysis, skin lesions (palpable purpura, reticular lividus, urticaria, etc.), mononeuritis multiplex, seizures, other nonspecific neurological complaints, abdominal pain, gastrointestinal bleeding, pain in the chest, pain in the eyes, sinusitis and pain in the testicles [7, 8, 10, 44]. Otolaryngological manifestations are less frequent in patients with MPA [10]. Possible cardiovascular manifestations include hypertension, signs of heart failure, myocardial infarction, and pericarditis [7].

Some patients may have an acute onset of fulminant disease with overt hemoptysis, hematuria, or even renal failure, [7], which occurred in the third clinical case.

Individuals may have an insidious onset of systemic symptoms such as fever, malaise, or weight loss, but more often the onset is acute in patients complaining of arthralgia and flu-like symptoms [7], which are thought to be the most common at the onset of MPA [22].

Therefore, attention is drawn to the polymorphism of non-specific clinical manifestations at the onset of the disease, which in the given clinical cases, except shortness of breath, practically did not recur and were represented by a diverse combination of them. If in the first case, the initial manifestation of MPA was a cardiac syndrome, which led to the patient's primary visit and long-term treatment to a cardiologist with a consultation with a cardiac surgeon, then in the 2nd case, in the early stages of the development of MPA, typical general symptoms prevailed (myalgias, shortness of breath, noticeable weight loss, malaise).

The course of MPA in the 2nd patient was characterized by a relatively slow onset with gradual deterioration of well-being and inevitable multisystem damage involving the kidneys, lungs, musculoskeletal system, skin, gastrointestinal tract, peripheral and central nervous system, i.e. polymorphism of the clinical picture and long-term high activity of the pathological process.

In the third patient, the first manifestations of MPA were fever, macrohematuria, and hemoptysis, and the generalization of the pathological process with the development of hyperazotemia, anemia, and hypercholesterolemia occurred less than three weeks after COVID-19, which corresponded to the acute course of the disease and is consistent with literature data [7]. In particular, Mendes et al believe that the onset of rheumatic diseases, especially small-vessel vasculitis and arthritis, usually occurs days to weeks after antigenic challenge and in patients with mild COVID-19 [32]. Interestingly, Morris and co-authors note that with the increasing number of people infected with SARS-CoV-2 and having only mild or no symptoms, unfortunately, an even larger cohort of critically ill patients is expected in the future [28]. Therefore, the polymorphism of non-specific clinical signs and multisystem clinical manifestations are characteristic features of the debut of MPA, which may differ from patient to patient, confuse the doctor and direct the diagnostic search in the wrong direction.

Real clinical practice proves that MPA is quite a common phenomenon in the practice of nephrologists [19] because MPA is a systemic weak-immune vasculitis of glomerular capillaries, which leads to necrotizing glomerulonephritis [10]. Renal manifestations are the most common, and 80% to 100% of individuals have some form of glomerulonephritis at onset or as the disease progresses. The most frequent and aggressive manifestation is the «low-immune» form of RPGN, which is manifested by the loss of kidney function (rapid decrease in GFR to  $\geq 50\%$ ) within a few days or weeks [22] up to 3 months [6, 8]. Clinical manifestations can be diverse: from asymptomatic microscopic hematuria, subnephrotic proteinuria (usually less than 3 g),

hypertension, increased creatinine, or overt renal failure [7, 8, 10]. It should be noted that MPA can be limited only to kidney damage without the involvement of other organs [10]. However, a biopsy is strongly recommended and provides the «gold standard» of diagnostic results, especially in the case of equivocal serology or an unusual clinical picture [8].

Rapidly progressing renal failure due to RPGN was the only common sign of MPA manifestation for all three presented patients. In two patients, RPGN was complicated by severe renal dysfunction, which led to the use of acute dialysis sessions in the treatment.

In all patients in the advanced stage of the disease, a bright clinical picture of RPGN was observed with a severe general condition, extremely high activity of the pathological process (as evidenced by an increase in non-specific inflammatory markers), a steady increase in the level of urea and creatinine, increasing renal dysfunction with the development of terminal uremia within several weeks (in particular, in the presented 3rd case) or months.

Renal involvement in MPA is of particular importance because it is associated with a poor prognosis and increased mortality, as demonstrated by the 3rd clinical case. It should be noted that, according to literature data, the prognosis for MPA was worse in patients with pulmonary-renal syndrome [10].

Lung damage in MPA occurs less often and is observed in 25-55% of cases [7]. The most common pulmonary manifestation is diffuse alveolar hemorrhage, which rarely occurs as an initial symptom in MPA [45], but some patients may have chronic interstitial fibrosis leading to respiratory failure. [43, 44]. Patients with lung involvement have shortness of breath, cough, pleuritic chest pain, and hemoptysis due to alveolar hemorrhage, which can sometimes be the first symptom of the disease [7, 10]. Moreover, as noted by Lababidi et al., hemoptysis is sometimes absent due to the ability of the alveoli to absorb significant amounts of blood before it spreads to the large airways [42]. Capillaritis with fibrinoid necrosis is a typical pathological feature in MPO-ANCA patients with lung involvement [12, 43].

Therefore, a comparative analysis of the chronological sequence of the course of MPA in the presented clinical cases demonstrates both the polymorphism of clinical manifestations in the early stage of the disease and different variants of its course in the advanced stage of MPA. If in the 1st case, a limited severity of clinical manifestations was observed on the part of other organs, then in the 2nd and 3rd cases – multisystem damage with polymorphism of clinical manifestations.

Among the presented cases, in one patient, COVID-19 and MPA were simultaneous, while in the other two patients, the duration was up to 6 months, which is consistent with literature data [3, 29].

It is well known that rapid diagnosis is essential to initiate therapy, which can both save lives and preserve

organs. This can be difficult due to the variability of clinical symptoms at the onset of MPA. As a rule, remission is achieved with the help of a combination of glucocorticoids and cyclophosphamide [7], which was obtained in the first two cases.

Studies by many scientists indicate acute kidney injury during COVID-19 [12, 35], which was a very common phenomenon and was confirmed by the results of pathomorphological studies of kidneys in patients who died of severe COVID-19 [46].

The results of the pathomorphological examination in the 3rd case demonstrated the presence in the kidneys of glomeruli collapsed due to extracapillary proliferation in the form of crescents with the formation of fibrocellular and fibrous structures. Dystrophic changes in the epithelium of renal tubules, its focal desquamation. Protein masses with surrounding leukocytes in the lumen of renal tubules. Lymphohistiocytic infiltrates with a small number of neutrophils in the renal interstitium, which is consistent with literature data [13, 22].

To understand the knowledge and perceptions of doctors about ANCA-associated vasculitis, a team of specialists from Great Britain, India, Kazakhstan and Ukraine from 8 leading scientific centers of the world developed an online questionnaire with 28 questions based on relevant global practice guidelines, recommendations on AAVs and conducted an online survey during the COVID-19 pandemic [47]. An assessment of the knowledge and perceptions of doctors about AAVs is presented in a report published on November 21, 2022, where respondents from 21 countries of the world indicated the need to strengthen medical education, which can increase the awareness and knowledge of practicing doctors about ANCA-vasculitis.

Since MPA and COVID-19 are interdisciplinary problems, patients with MPA, as well as patients with chronic kidney disease with post-covid syndrome [48], are subject to constant monitoring by an interdisciplinary team of doctors to prevent the development of complications or irreversible changes in the affected organs, ensure long-term remission, which will allow to extend life expectancy and improve its quality.

**Conclusions.** COVID-19 disease and ANCA-associated vasculitis are multisystem diseases that share both pathogenetic mechanisms of development and clinical manifestations, and there is a causal relationship between them. MPA and COVID-19 can affect the lungs and kidneys, which can lead to a delay in diagnosis. Features of the debut of MPA are the polymorphism of non-specific clinical manifestations and multiorgan lesions, which can differ from patient to patient, mislead the doctor and direct the diagnostic search in the wrong way, while during the manifestation of MPA, kidney damage by the type of GN, quite often RPGN and acute damage is characteristic kidney. In order to prevent the development of complications or irreversible changes in the affected organs, patients with MPA must be monitored by a multidisciplinary team of doctors. In today's conditions, there is a need to increase the awareness and knowledge of practicing doctors on AAV and MPA issues, as evidenced by the results of an online survey during the COVID-19 pandemic among doctors in 21 countries of the world.

**Conflict of interest.** The authors declare no conflict of interest.

**The authors' contributions.**

**Yarmola T.I.:** data collection and analysis, writing of the clinical case presentation section, preparation of the manuscript for publication, and final editing;

**Gutsalenko O.O.:** work concept and design, analysis of literary sources, article writing, preparation of the manuscript for publication, and literary editing;

**Katerenchuk I.P.:** analysis of literary sources, preparation of the manuscript for publication, and final editing;

**Tkachenko L.A.:** the idea of the work, analysis of literary sources, consultation examinations of the presented patients, assistance in verifying the diagnosis and their further management;

**Kostrikova Yu.A.:** analysis of literary sources, literary editing and preparation of the manuscript for publication, language editing, and final approval of the article;

**Talash V.V.:** analysis of literary sources, consultation examinations of the presented patients.

**References:**

1. Jennette JC, Falk RJ, Bacon PA, Basu N, Cid MC, Ferrario F, et al. 2012 revised International Chapel Hill Consensus Conference Nomenclature of Vasculitides. *Arthritis Rheum* 2013 Jan; 65(1):1–11. doi:10.1002/art.37715.
2. Jennette JC. Overview of the 2012 revised International Chapel Hill Consensus Conference nomenclature of vasculitides. *Clin Exp Nephrol*. 2013 Oct;17(5):603-606. doi: 10.1007/s10157-013-0869-6.
3. Thu Aung Z, Oluyombo R, Karim M, Wong Sun Wai J, Ugni S. SARS-CoV-2 Infection: A Forerunner or Precursor in Anti-neutrophil Cytoplasmic Antibody-Associated Vasculitis With Kidney Injury. *Cureus*. 2022 Sep 2;14(9):e28705. doi: 10.7759/cureus.28705.
4. Bataille PM, Durel CA, Chauveau D, Panes A, Thervet ES, Terrier B. Epidemiology of granulomatosis with polyangiitis and microscopic polyangiitis in adults in France. *J Autoimmun*. 2022 Dec;133:102910. doi: 10.1016/j.jaut.2022.102910.

5. *Geetha D, Jefferson JA*. ANCA-Associated Vasculitis: Core Curriculum 2020. *Am J Kidney Dis*. 2020 Jan;75(1):124-137. doi: 10.1053/j.ajkd.2019.04.031.
6. *Sinico RA, Di Toma L, Radice A*. Renal involvement in anti-neutrophil cytoplasmic autoantibody associated vasculitis. *Autoimmun Rev*. 2013 Feb;12(4):477-82. doi: 10.1016/j.autrev.2012.08.006.
7. *Hashmi MF, Jain V, Tiwari V*. Microscopic Polyangiitis. [Updated 2022 Nov 27]. In: StatPearls [Internet]. Treasure Island (FL): StatPearls Publishing; 2022 Jan-. [cited 2022 Dec 23]. Available from: [https://www.ncbi.nlm.nih.gov/books/NBK531484/#\\_NBK531484\\_pubdet](https://www.ncbi.nlm.nih.gov/books/NBK531484/#_NBK531484_pubdet). (Last accessed: 16.04.2023).
8. *Molnr A, Studinger P, Led N*. Diagnostic and Therapeutic Approach in ANCA-Associated Glomerulonephritis: A Review on Management Strategies. *Front Med (Lausanne)*. 2022 Jun 3;9:884188. doi: 10.3389/fmed.2022.884188.
9. *Jennette JC, Falk RJ, Andrassy K, Bacon PA, Churg J, Gross WL, et al*. Nomenclature of systemic vasculitides. Proposal of an international consensus conference. *Arthritis Rheum*. 1994 Feb;37(2):187-92. doi: 10.1002/art.1780370206.
10. *Dousdampanis P, Assimakopoulos SF, Trigka K*. Microscopic Polyangiitis: from Pathogenesis to Treatment. *Urol Nephrol Open Access J*. 2017 Aug 17;5(2):00167. doi: 10.15406/unoaj.2017.05.00167.
11. *Gelzo M, Cacciapuoti S, Pinchera B, et al*. A Transient Increase in the Serum ANCAs in Patients with SARS-CoV-2 Infection: A Signal of Subclinical Vasculitis or an Epiphenomenon with No Clinical Manifestations? A Pilot Study. *Viruses*. 2021 Aug 29;13(9):1718. doi: 10.3390/v13091718.
12. *Izci Duran T, Turkmen E, Dilek M, Sayarlioglu H, Arik N*. ANCA-associated vasculitis after COVID-19. *Rheumatol Int*. 2021 Aug;41(8):1523-1529. doi: 10.1007/s00296-021-04914-3.
13. *Madanchi N, Stingo FE, Patrick KC, Muthusamy S, Gupta N, Imran Fatani Y, et al*. Possible Association Between COVID-19 Infection and De Novo Antineutrophil Cytoplasmic Antibody-Associated Vasculitis. *Cureus*. 2021 Dec 10;13(12):e20331. doi: 10.7759/cureus.20331.
14. *Suppiah R, Robson JC, Grayson PC, Ponte C, Craven A, Khalid S, et al*. DCVAS Study Group. 2022 American College of Rheumatology/European Alliance of Associations for Rheumatology Classification Criteria for Microscopic Polyangiitis. *Arthritis Rheumatol*. 2022 Mar;74(3):400-406. doi: 10.1002/art.41983.
15. *Robson JC, Grayson PC, Ponte C, Suppiah R, Craven A, Judge A, et al*. DCVAS Investigators. 2022 American College of Rheumatology/European Alliance of Associations for Rheumatology classification criteria for granulomatosis with polyangiitis. *Ann Rheum Dis*. 2022 Mar;81(3):315-320. doi: 10.1136/annrheumdis-2021-221795.
16. *Grayson PC, Ponte C, Suppiah R, Robson JC, Craven A, Judge A, et al*. DCVAS Study Group. 2022 American College of Rheumatology/European Alliance of Associations for Rheumatology Classification Criteria for Eosinophilic Granulomatosis With Polyangiitis. *Arthritis Rheumatol*. 2022 Mar;74(3):386-392. doi: 10.1002/art.41982.
17. *Redondo-Rodriguez R, Mena-Vázquez N, Cabezas-Lucena AM, Manrique-Arija S, Mucientes A, Fernández-Nebro A*. Systematic Review and Metaanalysis of Worldwide Incidence and Prevalence of Antineutrophil Cytoplasmic Antibody (ANCA) Associated Vasculitis. *J Clin Med*. 2022 May 4;11(9):2573. doi: 10.3390/jcm11092573.
18. *Nilsen AT, Karlsen C, Bakland G, Watts R, Luqmani R, Koldingsnes W*. Increasing incidence and prevalence of ANCA-associated vasculitis in Northern Norway. *Rheumatology (Oxford)*. 2020 Sep 1;59(9):2316-2324. doi: 10.1093/rheumatology/kez597.
19. *Katerenchuk IP, Tkachenko LA, Yarmola TI, Talash VV*. Microscopic polyangiitis – a view of the problem through the lens of a nephrologist. *Wiad Lek*. [Internet]. 2021;74(4):1024-1031. Available from: <https://pubmed.ncbi.nlm.nih.gov/34156024/>. (Last accessed: 16.04.2023).
20. Reuters Health Information. Medscape [Internet]. China Estimates COVID Surge Is Infecting 37 Million People a Day. Reporting by Akriti Sharma in Bengaluru. Editing by Jane Merriman. Reuters staff. December 27, 2022. [cited 2022 Dec 23]. Available from: [https://www.medscape.com/viewarticle/986080?src=wnl\\_edit\\_tpal&uac=424012FN&impID=5041686&faf=1](https://www.medscape.com/viewarticle/986080?src=wnl_edit_tpal&uac=424012FN&impID=5041686&faf=1). (Last accessed: 16.04.2023).
21. Reuters Health Information. Medscape [Internet]. China COVID Deaths Accelerate to 9000 a Day: UK Research Firm Airfinity. Reporting by Ryan Woo and Joe Cash; Editing by Emelia Sithole-Matarise. Reuters staff. December 30, 2022. Available from: <https://www.medscape.com/viewarticle/986304>. (Last accessed: 16.04.2023).
22. *Allena N, Patel J, Nader G, Patel M, Medvedovsky B*. A Rare Case of SARS-CoV-2-Induced Microscopic Polyangiitis. *Cureus*. 2021 May 26;13(5):e15259. doi: 10.7759/cureus.15259.
23. *Varga Z, Flammer AJ, Steiger P, Haberecker M, Andermatt R, Zinkernagel AS, et al*. Endothelial cell infection and endotheliitis in COVID-19. *Lancet*. 2020 May 2;395(10234):1417-1418. doi: 10.1016/S0140-6736(20)30937-5.

24. *Giles T, Roy SP, Chandrasoma D, et al.* Life-threatening gastrointestinal haemorrhage requiring surgical resection caused by SARS-CoV-2 induced ANCA associated vasculitis: A case report. *Int J Surg Case Rep.* 2022 Sep;98:107491. doi: 10.1016/j.ijscr.2022.107491.
25. *Reiff DD, Meyer CG, Marlin B, et al.* New onset ANCA-associated vasculitis in an adolescent during an acute COVID-19 infection: a case report. *BMC Pediatr.* 2021 Aug 5;21(1):333. doi: 10.1186/s12887-021-02812-y.
26. *Bryant MC, Spencer LT, Yalcindag A.* A case of ANCA-associated vasculitis in a 16-year-old female following SARS-COV-2 infection and a systematic review of the literature. *Pediatr Rheumatol Online J.* 2022 Aug 13;20(1):65. doi: 10.1186/s12969-022-00727-1.
27. *Kronbichler A, Geetha D, Smith RM, et al.* The COVID-19 pandemic and ANCA-associated vasculitis – reports from the EUVAS meeting and EUVAS education forum. *Autoimmun Rev.* 2021 Dec;20(12):102986. doi: 10.1016/j.autrev.2021.102986.
28. *Morris D, Patel K, Rahimi O, et al.* ANCA vasculitis: A manifestation of Post-Covid-19 Syndrome. *Respir Med Case Rep.* 2021;34:101549. doi: 10.1016/j.rmcr.2021.101549.
29. *Seyda Ozcan, Ozge Sonmez, Cebrail Karaca, et al.* ANCA-associated vasculitis flare might be provoked by COVID-19 infection: a case report and a review of the literature. *Clinical Kidney Journal.* 2022 Nov; 15(11): 1987–1995. doi:10.1093/ckj/sfac186.
30. *Giryas S, Bragazzi NL, Bridgewood C, De Marco G, McGonagle D.* COVID-19 Vasculitis and vasculopathy-Distinct immunopathology emerging from the close juxtaposition of Type II Pneumocytes and Pulmonary Endothelial Cells. *Semin Immunopathol.* 2022 May;44(3):375-390. doi: 10.1007/s00281-022-00928-6.
31. *Gracia-Ramos AE, Martin-Nares E, Hernández-Molina G.* New Onset of Autoimmune Diseases Following COVID-19 Diagnosis. *Cells.* 2021 Dec 20;10(12):3592. doi: 10.3390/cells10123592.
32. *Mendes JL, Venade G, Manuel P, Costa Matos L, Nascimento E.* Virus and Autoimmunity: Can SARS-CoV-2 Trigger Large Vessel Vasculitis? *Eur J Case Rep Intern Med.* 2022 Aug 9;9(8):003486. doi: 10.12890/2022\_003486.
33. *Sacchi MC, Tamiazzo S, Stobbione P, Agatea L, De Gaspari P, Stecca A, et al.* SARS-CoV-2 infection as a trigger of autoimmune response. *Clin Transl Sci.* 2021 May;14(3):898-907. doi: 10.1111/cts.12953.
34. *Liu Y, Sawalha AH, Lu Q.* COVID-19 and autoimmune diseases. *Curr Opin Rheumatol.* 2021 Mar 1;33(2):155-162. doi: 10.1097/BOR.0000000000000776.
35. *Kataria S, Rogers S, Sadia H, Ali T, Qureshi HM, Bano S, et al.* Antineutrophil Cytoplasmic Antibody (ANCA)-Associated Renal Vasculitis After COVID-19 Infection: A Case Report. *Cureus.* 2022 Jun 20;14(6): e26111. doi:10.7759/cureus.26111.
36. *Ackermann M, Anders HJ, Bilyy R, Bowlin GL, Daniel C, De Lorenzo R, et al.* Patients with COVID-19: in the dark-NETs of neutrophils. *Cell Death Differ.* 2021 Nov;28(11):3125-3139. doi: 10.1038/s41418-021-00805-z.
37. *Barnes BJ, Adrover JM, Baxter-Stoltzfus A, Borczuk A, Cools-Lartigue J, Crawford JM, et al.* Targeting potential drivers of COVID-19: Neutrophil extracellular traps. *J Exp Med.* 2020 Jun 1;217(6):e20200652. doi: 10.1084/jem.20200652.
38. *Kronbichler A, Lee KH, Denicolo S, Choi D, Lee H, Ahn D, et al.* Immunopathogenesis of ANCA-Associated Vasculitis. *International Journal of Molecular Sciences.* 2020; 21(19):7319. doi:10.3390/ijms21197319.
39. *Lee LE, Jeong W, Park YB, Jeong SJ, Lee SW.* Clinical Significance of Antineutrophil Cytoplasmic Antibody Positivity in Patients Infected with SARS-CoV-2. *J Clin Med.* 2022 Jul 17;11(14):4152. doi: 10.3390/jcm11144152.
40. *Kawashima S, Kishimoto M, Hibino T, Lee H, Sato Y, Komagata Y, Kaname S.* MPO-ANCA-positive Microscopic Polyangiitis Following COVID-19 Infection. *Intern Med.* 2022 Feb 15;61(4):567-570. doi: 10.2169/internalmedicine.8615-21.
41. *Yates M, Watts RA, Bajema IM, Cid MC, Crestani B, Hauser T, et al.* EULAR/ERA-EDTA recommendations for the management of ANCA-associated vasculitis. *Ann Rheum Dis.* 2016 Sep;75(9):1583-94. doi: 10.1136/annrheumdis-2016-209133.
42. *Lababidi MH, Odigwe C, Okolo C, Elhassan A, Iroegbu N.* Microscopic polyangiitis causing diffuse alveolar hemorrhage and rapidly progressive glomerulonephritis. *Proc (Bayl Univ Med Cent).* 2015 Oct;28(4):469-71. doi: 10.1080/08998280.2015.11929311.
43. *Kallenberg CG.* The diagnosis and classification of microscopic polyangiitis. *J Autoimmun.* 2014 Feb-Mar;48-49:90-3. doi: 10.1016/j.jaut.2014.01.023.
44. *Karras A.* Microscopic Polyangiitis: New Insights into Pathogenesis, Clinical Features and Therapy. *Semin Respir Crit Care Med.* 2018 Aug;39(4):459-464. doi: 10.1055/s-0038-1673387.

45. Patel R, Amrutiya V, Baghal M, Shah M, Lo A. Life-Threatening Diffuse Alveolar Hemorrhage as an Initial Presentation of Microscopic Polyangiitis: COVID-19 as a Likely Culprit. *Cureus*. 2021 Apr 10;13(4):e14403. doi: 10.7759/cureus.14403.
46. Sovgiryа SN, Filenko BN, Roiko NV, Starchenko II, Pyatibratov AY, Kislіi VF. Morfo-patofiziologicheskie aspekty izmeneniya pochetk pri COVID-19. *Azerbaijan Medical Journal*. 2022;1:125–130. doi: 10.34921/amj.2022.1.020. [In Russian].
47. Auanassova A, Yessirkepov M, Zimba O, Gasparyan AY, Joshi M, Agarwal V, et al. Physicians' perceptions about antineutrophil cytoplasmic antibody-associated vasculitis: an online survey report in the time of the COVID-19 pandemic. *Clin Rheumatol*. 2023 Mar;42(3):831-837. doi: 10.1007/s10067-022-06452-0.
48. Kolesnyk M, Stepanova N. Post-COVID syndrome in dialysis patients and kidney transplant recipients. *Ukr J Nephrol Dial*. 2022;1(73):90-98. doi: 10.31450/ukrjnd.1(73).2022.10.