



Ukrainian Journal of Nephrology and Dialysis

Scientific and Practical, Medical Journal

Founder:

- National Kidney Foundation of Ukraine

ISSN 2304-0238;
eISSN 2616-7352

Journal homepage: <https://ukrjnd.com.ua>

Research article

Mohammed N. Abed, Mohannad E. Qazzaz, Fawaz A. Alassaf

doi: 10.31450/ukrjnd.2(82).2024.05

Investigating the nephrotoxic effects of medroxyprogesterone in female albino rats

College of Pharmacy, University of Mosul, Iraq

Citation:

Abed MN, Qazzaz ME, Alassaf FA. Investigating the nephrotoxic effects of medroxyprogesterone in female albino rats. Ukr J Nephrol Dial. 2024;2(82): 25-33. doi: 10.31450/ukrjnd.2(82).2024.05.

Abstract. *Progestins, though integral to various bodily functions as endogenous hormones, have been associated with adverse effects when administered exogenously in excessive amounts. This study investigates the impact of medroxyprogesterone (MePro) on kidney function, examining biochemical parameters, histology, and oxidative stress markers.*

Methods. *Twenty healthy adult female Albino rats were assigned to four groups: Group 1 consisted of 10 rats before MePro treatment, Group 2 comprised the same rats 8 weeks after intramuscular MePro administration (3.5 mg/week), Group 3 served as the control group, and Group 4 represented the same rats as Group 3 at the conclusion of the study. Serological and histological markers of renal damage, as well as parameters of oxidative stress (malondialdehyde, MDA) and antioxidant status (total antioxidant status, TAS), were investigated in female albino rats following MePro administration.*

Results. *MePro administration resulted in notable increases in weight, urea, creatinine, and MDA levels, alongside a decrease in TAS compared to baseline levels ($p < 0.001$). Conversely, the control groups showed no significant changes in these parameters over time. Creatinine levels and oxidative stress markers in Group 2 were notably higher than those in Groups 3 and 4 ($p < 0.001$). Post-MePro administration, renal histopathology revealed significant deposition of hyaline casts in the tubular lumens, along with vascular lesions, hemorrhage, and inflammation.*

Conclusions. *The decline in kidney function, antioxidant status, and propensity for renal injury associated with MePro use underscore its potential renal toxicity.*

Key words: *kidney function, medroxyprogesterone, progestins, renal toxicity, oxidative stress.*

Conflict of interest. The authors declare no conflict of interest.

© M. N. Abed, M. E. Qazzaz, F. A. Alassaf, 2024.

Correspondence should be addressed to Mohammed N. Abed: m.n.abed@uomosul.edu.iq

Article history:

Received January 15, 2024

Received in revised form

February 02, 2024

Accepted February 12, 2024



© Абед М. Н., Каззас М. Е., Аласаф Ф. А., 2024.

УДК: 616.61:577.152.1:615.357]:599.323.4

Мохаммед Н. Абед, Моханнад Е. Каззас, Фаваз А. Аласаф

Дослідження нефротоксичних ефектів медроксипрогестерону у самок щурів-альбіносів

Фармацевтичний коледж Університету Мосула, Ірак

Резюме. Прогестини, синтетичні аналоги прогестерону, відіграють важливу роль у функціонуванні жіночого організму, але їх застосування в екзогенній формі у великих дозах може призвести до негативних наслідків. Це дослідження мало на меті визначити вплив медроксипрогестерону (MePro) на функцію нирок, гістологічний патерн ниркової тканини, та показники оксидативного стресу.

Методи. Двадцять здорових дорослих самок щурів-альбіносів було розподілено на чотири групи: Група 1 складалась з 10 щурів до лікування MePro, Група 2 включала тих самих щурів через 8 тижнів після внутрішньом'язового введення MePro (3,5 мг/тиждень), Група 3 служила контролем. Група 4 представляла тих самих щурів, що й Група 3 на момент завершення дослідження. Досліджували серологічні та гістологічні маркери ураження нирок, а також параметри оксидативного стресу (малоновий діальдегід, МДА) і антиоксидантний статус (загальний антиоксидантний статус, ЗАС) у самок щурів-альбіносів після введення MePro.

Результати. Застосування MePro призвело до помітного збільшення ваги, концентрації сечовини, креатиніну та МДА, а також зниження рівня ЗАС крові порівняно з вихідним рівнем ($p < 0,001$). Інакше, контрольні групи не показали значних змін досліджуваних параметрів з часом. Рівні креатиніну та маркери оксидативного стресу в групі 2 були помітно вищими, ніж у групах 3 і 4 ($p < 0,001$). За даними гістологічного дослідження, визначено значне відкладення гіалінових циліндрів у просвітах каналців та виражені судинні зміни нирок щурів після введення MePro.

Висновки. Зниження функції нирок, антиоксидантного статусу та пошкодження нирок за даними гістологічного дослідження ниркової тканини, асоційовані з використанням MePro, підкреслюють його потенційну токсичність для нирок.

Ключові слова: функція нирок, медроксипрогестерон, прогестини, нефротоксичність, оксидативний стрес.

Introduction. Medroxyprogesterone (MePro), a 17α -derivative of hydroxyprogesterone, is synthetically prepared as an analog of progesterone [1]. Both hormones play critical roles in controlling the immune system. MePro is the most extensively prescribed injectable contraceptive since its introduction more than 3 decades ago. It is a contraceptive with long-action used by more than 20 million women currently around the world [2, 3]. MePro can also be used to treat menopause symptoms in combination with estrogen as a part of hormone replacement therapy. MePro is frequently utilized in malignancies, both in the endocrine treatment of hormone-related tumors, such as cancers of the breast, ovaries, and endometrium, and also as an adjunctive treatment in patients suffering from anorexia/cachexia syndrome [4, 5]. Additionally, to minimize the risk of uterine cancer, MePro is administered with estrogen as a replacement therapy [6]. When considering therapeutic decisions for postmenopausal women, analyzing the impact of hormon-

al replacement therapy on the kidneys is regarded as a critical clinical consideration [7]. Furthermore, the therapeutic potential of MePro could be halted if an adverse impact occurs, necessitating a re-evaluation of the drug's benefit/risk profile. Menstrual disorders, alterations in bleeding patterns, dizziness, headache, nervousness, weight fluctuations, abdominal discomfort, and exhaustion are among the most apparent side effects. In older women utilizing MePro with estrogen for postmenopausal hormone replacement therapy, a slight rise in relative risk of stroke and breast carcinoma, as well as a deterioration in cognitive ability, have been noted. Back pain, myalgia, gradually reduced libido or sexual dysfunction, sleeping problems, depression, nausea, debilitated bone mineral density throughout adolescence and facilitated bone loss in older age, leukorrhea, pelvic pain, breast pain, digestive problems, acne, vaginitis, alopecia, hot flashes, rash, and edema are some of the other side effects [8]. Moreover, women using MePro have a greater risk of acquiring HIV-1 infection due to the deterioration of the integrity of cervicovaginal mucosa in response to MePro [9]. Despite knowing that progestins are natural hormones produced by the body, excessive amounts can have negative health consequences, as seen by the above-mentioned side effects. Therefore, it is still questionable if progestins as birth control substances are allies or foes.

Mohammed N. Abed

m.n.abed@uomosul.edu.iq

The study aimed to explore the possible impact of MePro on the kidney by investigating the parameters of kidney function and kidney histological pattern, in addition to studying the outcomes of MePro on the oxidative stress markers and antioxidant status in female albino rats following the use of MePro.

Materials and methods. All experiments received approval from the university's animal welfare

committee, and ethical clearance was obtained from the Medical Research Ethics Collegiate Committee (code: CCMRE-phA-23-9). Prior to commencement, it was ensured that all animals were housed in suitable conditions and received appropriate care. The experimental design is depicted in Figure 1.

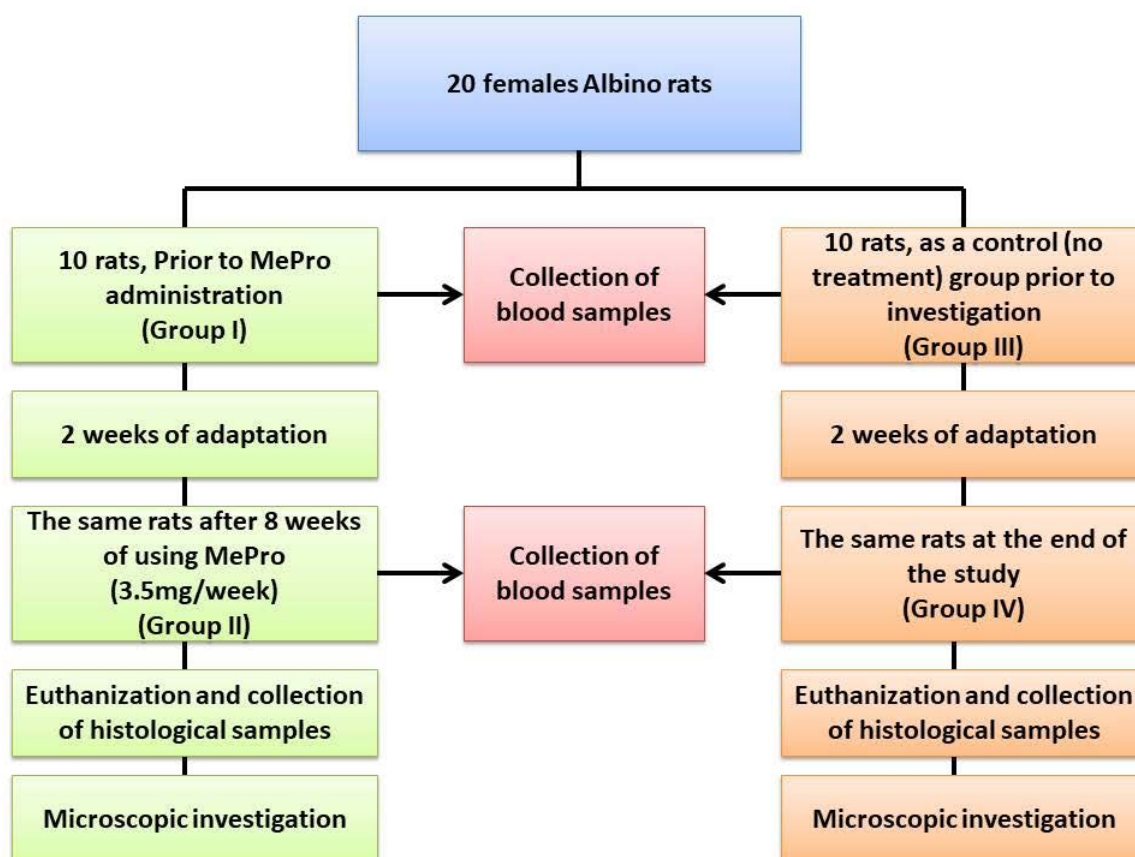


Fig. 1. The experiment design.

Twenty adult female albino rats were randomly assigned to groups of ten rats each, aged between 4-5 months and weighing between 175-275 g. The rats were sourced from the animal house at the College of Veterinary Medicine, University of Mosul, and the study was conducted from August 2022 to January 2023. Group I comprised female albino rats before MePro administration, while Group II consisted of the same animals after MePro administration. Group III served as the control group at the trial's onset, with Group IV representing the same animals as Group III at the trial's conclusion. The rats were housed in metal cages and acclimatized for two weeks, during which they were exposed to a 12/12-hour light/dark photoperiod, maintained at a humidity of approximately 45-50%, and kept at a temperature of $25 \pm 2^\circ\text{C}$, with free access to food and water. MePro was administered via intramuscular route at a dose of 3.5 mg/rat weekly for 8 weeks. Blood samples were collected from the lateral tail vein of all animals

at the beginning and end of the 8-week period. Prior to collection, the blood collection site was cleaned with 70% ethanol and locally anesthetized. The rat was restrained using a specific restrainer, and blood was withdrawn using a 21-gauge syringe, following recommended procedures outlined in the literature [10].

Biochemical measurements. To evaluate the renal function of rats, blood urea and serum creatinine levels were assessed. Urea levels were quantitatively determined using a colorimetric method with a kit from Biolabo, France. The assay utilized specific reagents including salicylate, nitroprussiate, urease, sodium hypochlorite, sodium hydroxide, and a standard urea solution, with spectrophotometer readings taken at a wavelength of 600 nm. Creatinine levels were measured using a kinetic colorimetric method based on the Jaff reaction, employing a kit from Roche/Hitachi cobas c systems, Germany, with reagents including potassium hydroxide, phosphate, and picric acid.

Malondialdehyde (MDA) levels were quantified using a lipid peroxidation assay kit from Abcam, UK. The assay involved the addition of thiobarbituric acid (TBA) solution to standards and samples, followed by incubation, cooling, transfer to a 96-well plate, and analysis with a microplate reader at 532 nm. Total antioxidant status (TAS) in plasma was estimated using Cayman's Antioxidant Assay kit from Cayman Chemical, USA. The kit provided lyophilized powders for various reagents including antioxidant assay buffer, chromogen, metmyoglobin, trolox, and hydrogen peroxide. Reagents were prepared according to the manufacturer's instructions, and absorbance readings for each sample and standard were obtained at 750 nm or 405 nm using a plate reader [11].

Animal euthanasia and kidney tissue collection.

At the end of the experiment, rats were euthanized to collect kidney tissue samples for histological examination. Euthanasia was conducted following guidelines

from the American Veterinary Medical Association (AVMA), using diethyl ether vapor inhalation in a glass desiccator.

Statistical analysis. The study data are presented as mean \pm SD (standard deviation). Pre-drug and post-drug administration effects within each group were compared using paired t-tests, as indicated in the text and figures. Results with $p < 0.05$ were considered statistically significant. Statistical differences between the groups were analyzed using one-way ANOVA, followed by Tukey's post hoc test to determine significant differences in means, as specified. A p -value < 0.05 was considered statistically significant. GraphPad Prism 8 was used for all statistical analyses.

Results. Biochemical Data Analysis. A significant increase in urea, serum creatinine, and MDA, along with a significant decrease in TAS, was observed when comparing pre- and post-administration results on the studied parameters ($p < 0.001$), as indicated in Table 1.

Table 1

Comparison of kidney function and oxidant/antioxidant status markers between medroxyprogesterone treated and control groups at baseline and end of study

Medroxyprogesterone treated group			
Parameter	Before	After	p.value
Urea (mg/dl)	29.6 \pm 4.4	33.5 \pm 4.3	<0.001
Creatinine (mg/dl)	0.32 \pm 0.05	1.05 \pm 0.12	<0.001
MDA (μ mol/L)	13.2 \pm 0.8	16.2 \pm 1	<0.001
TAS (mM)	1.44 \pm 0.1	1.15 \pm 0.1	<0.001
Control (untreated) group			
Urea (mg/dl)	30.7 \pm 2.9	30 \pm 3.4	NS
Creatinine (mg/dl)	0.33 \pm 0.04	0.34 \pm 0.03	NS
MDA (μ mol/L)	13.1 \pm 0.6	13.4 \pm 0.8	NS
TAS (mM)	1.42 \pm 0.12	1.43 \pm 0.08	NS

MDA: malondialdehyde, TAS: total antioxidant status, NS: non-significant.

In contrast, no deviations were observed in the tested values of the control group at the end of the investigation, as illustrated in Table 1.

Comparison of kidney function parameters among the four study groups revealed that blood urea levels in group 1 were significantly lower than in group 2 at $p < 0.001$. However, no other differences were observed between the other groups, as depicted in Figure 2A.

Serum creatinine levels exhibited significant changes after treatment (group 2) compared to before MePro administration (group 1), as well as control levels before and after the study endpoint, with $p < 0.001$. The data for creatinine before MePro administration were comparable to the control group, showing no significant difference, as illustrated in Fig. 2B.

Regarding oxidative stress parameters, the results indicated a statistically significant increase in serum MDA levels alongside a significant reduction in TAS in group 2 compared to the other groups included, at $p < 0.001$. No other noticeable differences were observed among the other studied groups, as outlined in Fig. 2C and D, respectively.

Observational results before dissection. Throughout the study period, no loss of any evaluated rats occurred in any of the groups. Overall, the rats exhibited normal physical activity and food consumption, with a significant increase in weight. Figure 3 compares the weights of rats before and after MePro administration across the studied groups, highlighting a notable difference, as depicted in the figure.

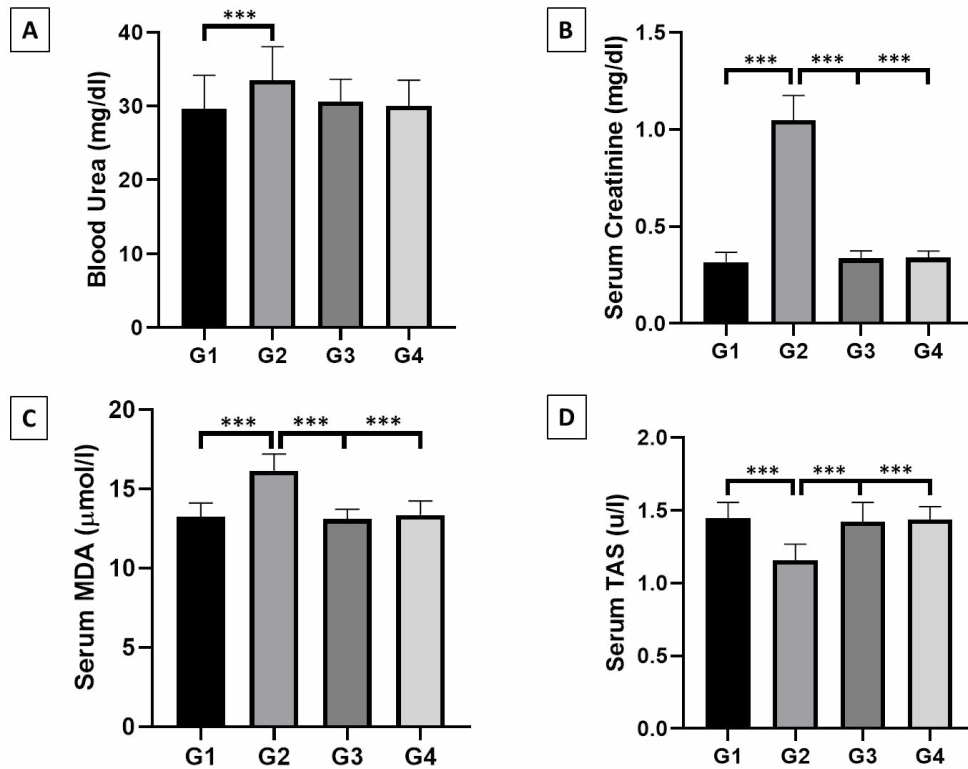


Fig. 2. Comparison of blood urea, serum creatinine, MDA, and TAS results between the explored groups.

The results are stated as mean±SD for each bar in the figure and the studied groups are shown to be different statistically (wherever specified at *** $p < 0.001$) via using one-way ANOVA. Such differences in mean values were judged using Tukey's post hoc test. (A) Comparison of blood urea between the studied groups shows a significant difference between G1 and G2. (B), (C) and (D) Comparison of serum creatinine, MDA and TAS, respectively, between the studied groups shows that G2 is significantly different from the other studied groups. G1: group 1. G2: group 2. G3: group 3. G4: group 4.

Abbreviations: MDA, malondialdehyde. TAS, total antioxidant status.

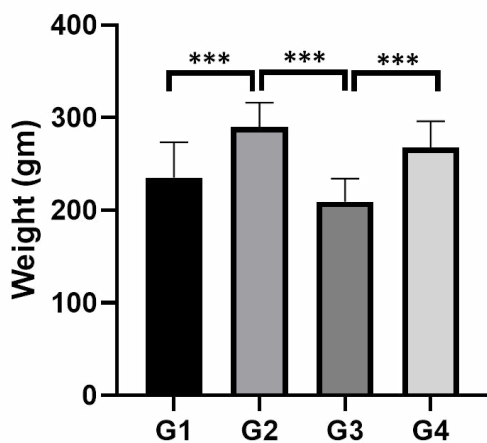


Fig. 3. Comparison of weight between the studied groups.

The results are formatted as mean±SD for each bar. Comparison between groups is indicated to be significant at *** $p < 0.001$, using one-way ANOVA. Such differences in mean values were judged using Tukey's post hoc test. G1: group 1. G2: group 2. G3: group 3. G4: group 4. gm: gram.

Kidney observations and histological findings. The kidney morphological observations revealed normal architecture of glomeruli and renal tubules among the control rats. The only exception was the presence of congestion in some blood vessels with mild hemorrhage (Fig. 4).

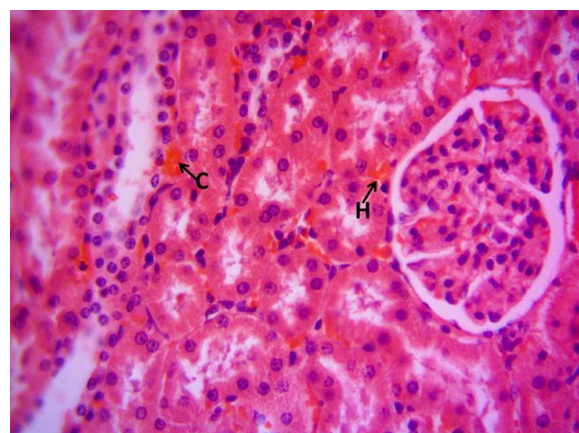


Fig. 4. Photomicrograph of the control's kidney at the end of the study period. The normal architecture of glomeruli and kidney tubules apart from the presence of mild congestion (C) and hemorrhage (H). H and E stain, 400X.

In contrast, renal histopathology following medroxyprogesterone use (Group 2) showed extensive deposition of hyaline casts in the renal tubule lumens, indicating tubular and interstitial lesions. Additionally, vascular lesions, hemorrhage, and inflammatory cell infiltration were evident, indicating a detrimental effect of MePro on the rats' kidneys (Fig. 5). This disparity in histological findings between the two groups clearly indicates the damaging effect of MePro on kidney tissue, leading to subsequent impairment in renal function.

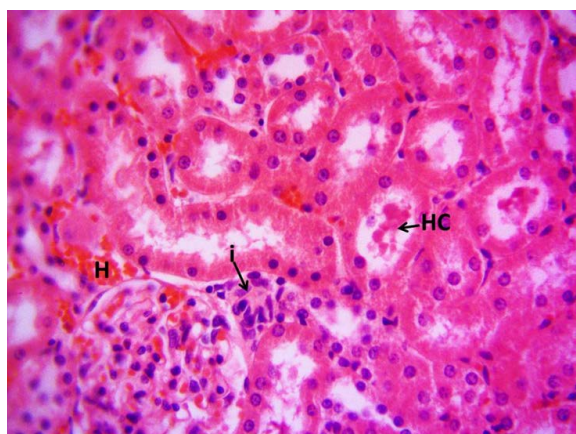


Fig. 5. Photomicrograph of kidney after 8 weeks of using medroxyprogesterone. Deposition of pretentious material (hyaline casts) in the lumen of renal tubules (HC), hemorrhage (H) with inflammatory cell infiltration (i). H and E stain, 400X.

Discussion. Progesterone, as a steroid sex hormone, has been proven to be crucial for a variety of bodily functions, including the stimulation and maintenance of pregnancy, reno-protection, in addition to regulation of the immune system. However, research revealed that such effects are not always true for exogenously administered sex hormones [12]. Oral estrogen therapy was shown to be associated with a decline in kidney function in postmenopausal females [13]. Similarly, exogenous progesterone has also been proven to have deleterious effects on the kidneys when compared to endogenous progesterone, with some studies having reported that the stronger the androgenic and progestational effect of progesterone, used mostly in contraceptive pills, the greater the stimulation of the renin-angiotensin-aldosterone system (RAAS) and the negative kidney outcomes [14]. Also, estradiol protected against proteinuria and glomerulosclerosis in ovariectomized rats with 5 out of 6 renal ablation, whereas rats injected with estradiol and progesterone had similar kidney damage as control. Progesterone, in this scenario, is predisposed to kidney damage [15]. The current study is in agreement with the above findings by demonstrating that MePro may have deleterious effects on the kidney as revealed from biochemical and observational investigations. Such a consequence can probably be augmented due to the negative effects of MePro on oxidative stress parameters. However, one study disagreed with this consequence by showing that acute progesterone administration was associated with reduced urinary

excretion of potassium in comparison to control with no other apparent changes in kidney function [16]. Obviously, sex hormones are linked with the advancement of chronic kidney damage to end-stage kidney disease (ESKD). But, on the other hand, ESKD has a clear sexual dimorphism in terms of incidence and prevalence. The incidence of ESKD is much higher in males than in females across all age categories, according to the research records [17, 18]. This is presumably because male hormones have negative impacts on oxidative stress, activation of the RAAS, and progressive fibrosis within the injured kidney [19]. Interestingly, the database of research also shows that the prevalence of chronic renal disease in males is substantially lower than in females [20]. In addition, the current research has revealed a negative impact of MePro on oxidative stress parameters, a case which could predispose to a wide range of adverse reactions if the drug is used chronically. Generally, the pathophysiology of several diseases and disorders including renal disorders has been linked to oxidative stress [21]. The high amount of reactive oxygen species (ROS) causes oxidative stress, which leads to either more ROS production or a reduction in antioxidant capacity. Oxidative stress occurs when cells produce more ROS than their intrinsic antioxidant capacity, resulting in damage to normal cells and tissues. ROS can attack basic organic substances such as proteins, nucleic acids, fatty acids (especially polyunsaturated), and, to a slightly lesser degree, carbohydrates [22]. This effect was noticed when MePro was administered with 17β -estradiol for 8 weeks in ovariectomized rats, where increased cardiac-ROS production and myocardial over-expression of NADPH oxidase subunits were increased and potentially linked to impaired left ventricular function. These findings support the hypothesis that adding MePro to a 17β -estradiol medication complicates post-myocardial infarction (MI) cardiovascular injury and thus helps to explain the negative results of prospective clinical investigations due to the disturbance of oxidant/antioxidant status [23]. Also, ovarian oxidative stress was prominent in female Wistar rats receiving depot of MePro for 4 weeks, indicating a negative role for MePro on antioxidant status [24]. The proposed mechanism of renal pathophysiology due to progesterone derivatives use is still unclear. However, progesterone may be converted into testosterone and dihydrotestosterone in the kidney by the 5- α reductase enzyme. As a result, part of the proposed progesterone's negative renal effects could be attributed to its androgenic actions [25]. Additionally, progesterone receptors have been detected in the medulla and cortex of both females and males, albeit they are mostly concentrated in distal tubule cells [26]. Progesterone occupies the mineralocorticoid receptor (MR) with an excessive affinity, where it can work as an MR antagonist [27]. Progesterone alone or in combination with estrogen attenuated kidney damage in rats mediated by the MR, proposing that progesterone may have functioned as an MR antagonist. Progesterone, on the other hand, could

be processed in the kidneys to some metabolites with a decreased potential for MR [28].

Considering the clinical implications, MePro administration in the present study was shown to harm the kidneys after 8 weeks of administration in female Albino rats. However, the use of this hormone in humans may extend extensively beyond such a period. Long-term exposure to MePro may subject the individuals to augmented deleterious consequences on the kidneys and is predicted to predispose them to further complications in the other organs and body systems. Commonly, prolonged usage of the slowly released depot of MePro acetate has been practiced in many clinical settings for controlling birth and as a replacement hormone [29]. A series of complications have been linked to the overuse of MePro for long periods, which may be due to reduced circulating estrogen. This action could predispose to multiple disadvantages including blood vessel problems, boosted mass of body fat, weight gain, amenorrhea, or irregular bleeding [30]. The Long-term use of these contraceptives at a young age may be associated with cardiovascular complications in the future due to endothelial dysfunction [31]. Additionally, investigating the effect of prolonged use of MePro (more than 2 years) on lipid profile in healthy women revealed a significant increase in LDL and cholesterol levels in comparison to the control [32]. Furthermore, lower extremities deep vein thrombosis, insulin resistance with abnormal high glucose levels, and increased fracture risk have been recently reported in a female who has received depot of MePro acetate for around 10 years [33]. All of these findings highlight the importance of following strict indications scenarios for this drug while paying more attention to the possible disadvantages on body organs. Moreover, monitoring the parameters of renal function, lipid profile, glycemic status and cardiovascular health are also advised in long-term users. It is also important to inform the women about predicted risks of prolonged use, where off-periods are recommended to avoid such complications.

While the present study used an animal model, translation of the observed nephrotoxic effects of MePro to real-world scenarios for women using this drug for contraception or hormone replacement therapy is essential. In general, there are many well-documented instances of drugs' effects in animals in which the revealed outcomes were applied to human models [34]. However, there is still little consensus on the impact of hormone replacement therapy on kidney function due to the limited and inconsistent clinical data in humans. Nonetheless, the revealed nephrotoxic potential of MePro in the present study may warn of the potential risk of using this hormone, especially for a long period. It has been shown in a survey of nephrologists that more than 43% of women are unaware of the effect of menopausal hormone replacement or contraceptives, indicating that increased awareness is needed in order to avoid the possible dangerous ef-

fects of exogenous hormones on the kidney and other organs in healthy women and in those with impaired renal function [35]. The present study used female rats at the age of fertility as a model to reveal that MePro administration has adverse outcomes on kidney function and histology. Such finding highlights that when MePro is administered to women may result in negative consequences on the kidneys, especially in those who are more susceptible to kidney damage or in patients with compromised renal function. Such findings may help healthcare professionals to decide the optimal choice of hormone replacement therapy on a personalized basis or to suggest other methods of contraception. Future studies are recommended to reveal the exact molecular mechanism through which MePro impact the overall health of the kidney and whether the produced renal toxicity is augmented with prolonged use of this drug.

Limitations. The primary limitation of the study was the small sample size. To extrapolate the findings, larger sample sizes and human-based clinical trials, especially those involving long-term administration of progestins with long elimination half-lives like MePro, are necessary.

Conclusions. The exogenously administered progesterone in this study predisposed to renal damage, reflected by a significant increase in urea and creatinine with kidney morphological changes and extensive deposition of hyaline casts in the lumen of renal tubules, vascular lesions, hemorrhage, and infiltration of inflammatory damage. Additionally, the oxidative stress status deteriorated, potentially exacerbating the negative impact on the kidneys and other organs. However, the specific underlying mechanisms behind the deleterious effects of exogenously administered progesterone on the kidney in premenopausal and postmenopausal females, as well as its impact on oxidative stress status, should be the focus of future investigations.

Conflict of interest. The authors have no conflict of interest to declare.

Funding sources. This study was not supported by any sponsor or funder.

Authors' contributions.

Mohammed N. Abed: conceptualization and design, experiment, data collection;

Mohannad E. Qazzaz: conceptualization and design, data analysis;

Fawaz A. Allassaf: experiment, data collection, and interpretation.

All authors have contributed equally in drafting the manuscript and approval of the final version.

Acknowledgment. We extend our special thanks and appreciation to the University of Mosul and the College of Pharmacy for their unwavering support throughout this study.

References:

1. Qazzaz ME, Abed MN, Alassaf FA, Jasim MHM, Alfahad M. Insights into the perspective correlation between vitamin D and regulation of hormones: sex hormones and prolactin. *Curr Issues Pharm Med Sci.* 2021;34(4):192–200. doi: 10.2478/cipms-2021-0035.
2. Piccinni MP, Lombardelli L, Logiodice F, Kullolli O, Maggi E, Barkley MS. Medroxyprogesterone Acetate Decreases Th1, Th17, and Increases Th2 Responses via AHR Signaling Which Could Affect Susceptibility to Infections and Inflammatory Disease. *Front Immunol.* 2019;10:642. doi: 10.3389/fimmu.2019.00642.
3. Brownell EA, Fernandez ID, Howard CR, Fisher SG, Ternullo SR, Buckley RJJ, et al. A Systematic Review of Early Postpartum Medroxyprogesterone Receipt and Early Breastfeeding Cessation: Evaluating the Methodological Rigor of the Evidence. *Breastfeed Med.* 2012;7(1):10–8. doi: 10.1089/bfm.2011.0105.
4. Ibrahim SL, Abed MN, Mohamed G, Price JC, Abdullah MI, Richardson A. Inhibition of branched-chain alpha-keto acid dehydrogenase kinase augments the sensitivity of ovarian and breast cancer cells to paclitaxel. *Br J Cancer.* 2023;128(5):896–906. doi: 10.1038/s41416-022-02095-9.
5. Uche FI, Abed MN, Abdullah MI, Drijfhout FP, McCullagh J, Claridge TWD, et al. Isochondrodendrine and 2'-norcocouline: additional alkaloids from *Triclisia subcordata* induce cytotoxicity and apoptosis in ovarian cancer cell lines. *RSC Adv.* 2017;7(70):44154–61. doi: 10.1039/C7RA08032H.
6. Kaunitz AM, Manson JE. Management of Menopausal Symptoms. *Obstet Gynecol.* 2015;126(4):859–76. doi: 10.1097/AOG.0000000000001058.
7. Zimmerman MA, Ogola BO, Wilkinson MM, Visniauskas B, De Miguel C, Daniel JM, et al. Medroxyprogesterone opposes estradiol-induced renal damage in midlife ovariectomized Long Evans rats. *Menopause.* 2020;27(12):1411–9. doi: 10.1097/GME.0000000000001675.
8. Dragoman MV, Gaffield ME. The safety of subcutaneously administered depot medroxyprogesterone acetate (104 mg/0.65 mL): A systematic review. *Contraception.* 2016;94(3):202–15. doi: 10.1016/j.contraception.2016.02.003.
9. Noguchi LM, Richardson BA, Baeten JM, Hillier SL, Balkus JE, Chirenje ZM, et al. Risk of HIV-1 acquisition among women who use different types of injectable progestin contraception in South Africa: a prospective cohort study. *Lancet HIV.* 2015;2(7):e279–87. doi: 10.1016/S2352-3018(15)00058-2.
10. Parasuraman S, Raveendran R, Kesavan R. Blood sample collection in small laboratory animals. *J Pharmacol Pharmacother.* 2010;1(2):87–93. doi: 10.4103/0976-500X.72350.
11. Thanoon IAJ, Jasim MHM, Abed MN, Alassaf FA, Qazzaz ME, Alfahad M. Effects of Omega-3 on Renal Function Tests and Uric Acid Level in Healthy Volunteers. *Lat Am J Pharm.* [Internet]. 2021;40(10):2319–2323. Available from: http://www.latamjpharm.org/resumenes/40/10/LAJOP_40_10_1_6.pdf.
12. Burgner A, Hladunewich MA. Contraception and CKD. *Clin J Am Soc Nephrol.* 2020;15(4):563–5. doi: 10.2215/CJN.09770819.
13. Ahmed SB, Culleton BF, Tonelli M, Klarenbach SW, MacRae JM, Zhang J, et al. Oral estrogen therapy in postmenopausal women is associated with loss of kidney function. *Kidney Int.* 2008;74(3):370–6. doi: 10.1038/ki.2008.205.
14. Sarna MA, Hollenberg NK, Seely EW, Ahmed SB. Oral contraceptive progestins and angiotensin-dependent control of the renal circulation in humans. *J Hum Hypertens.* 2009;23(6):407–14. doi: 10.1038/jhh.2008.148.
15. Antus B. Estradiol is nephroprotective in the rat remnant kidney. *Nephrol Dial Transplant.* 2003;18(1):54–61. doi: 10.1093/ndt/18.1.54.
16. Elkarib AO, Garland HO, Green R. Acute and chronic effects of progesterone and prolactin on renal function in the rat. *J Physiol.* 1983;337:389–400. doi: 10.1113/jphysiol.1983.sp014630.
17. Latief M, Yadla M, Abbas F. Assessment of sex hormones and their correlation with the quality of life in male hemodialysis patients. *Ukr J Nephrol Dial.* 2022;3(75):28–33. doi: 10.31450/ukrjnd.3(75).2022.04.
18. Hadid khalil A, Alassaf F, Abed M. Mechanisms and Linkage of Insulin Signaling, Resistance, and Inflammation. *Iraqi J Pharm.* 2024 Dec 22;21(1):1–8. doi: 10.33899/iph.2023.144181.1065.
19. Denova L. Development of renal fibrosis in patients with chronic kidney disease: Mechanisms, biomarkers, and clinical implications. *Ukr J Nephrol Dial.* 2023;3(79):54–67. doi: 10.31450/ukrjnd.3(79).2023.08.
20. Valdivielso JM, Jacobs-Cachá C, Soler MJ. Sex hormones and their influence on chronic kidney disease. *Curr Opin Nephrol Hypertens.* 2019;28(1):1–9. doi: 10.1097/MNH.0000000000000463.
21. Alfahad M, Qazzaz ME, Abed MN, Alassaf FA, Jasim MHM. Comparison of Anti-Oxidant Activity of Different Brands of Esomeprazole Available in Iraqi Pharmacies. *Syst Rev Pharm.* 2020;11(05):330–4. doi: 10.31838/srp.2020.5.48.

22. *Alfahad M, Jasim MHM, Qazzaz ME, Alassaf FA, Abed MN.* Proton pump inhibitors and peptic ulcer management: Antioxidant mechanisms. *J Drug Deliv Ther.* 2021;11(4-S):242–6. doi: 10.22270/jddt.v11i4-S.4955.
23. *Saeed K, Jo MH, Park JS, Alam SI, Khan I, Ahmad R, et al.* 17 β -Estradiol Abrogates Oxidative Stress and Neuroinflammation after Cortical Stab Wound Injury. *Antioxidants.* 2021;10(11):1682. doi: 10.3390/antiox10111682.
24. *Ismiyati A, Wiyasa IWA, Hidayati DYN.* Protective Effect of Vitamins C and E on Depot-Medroxyprogesterone Acetate-Induced Ovarian Oxidative Stress In Vivo. *J Toxicol.* 2016;2016:3134105:1–4. doi: 10.1155/2016/3134105.
25. *Yanes LL, Sartori-Valinotti JC, Reckelhoff JF.* Sex Steroids and Renal Disease. *Hypertension.* 2008;51(4):976–81. doi: 10.1161/HYPERTENSIONAHA.107.105767.
26. *Bumke-Vogt C, Bahr V, Diederich S, Herrmann S, Anagnostopoulos I, Oelkers W, et al.* Expression of the progesterone receptor and progesterone-metabolising enzymes in the female and male human kidney. *J Endocrinol.* 2002;175(2):349–64. doi: 10.1677/joe.0.1750349.
27. *Gomez-Sanchez E, Gomez-Sanchez CE.* The Multifaceted Mineralocorticoid Receptor. *Comprehensive Physiology.* 2014;4(3):965–94. doi: 10.1002/cphy.c130044.
28. *Montezano ACI, Callera GE, Mota AL, Fortes ZB, Nigro D, Carvalho MHC, et al.* Endothelin-1 contributes to the sexual differences in renal damage in DOCA-salt rats. *Peptides.* 2005;26(8):1454–62. doi: 10.1016/j.peptides.2005.03.038.
29. *Upton K, Harmon QE, Heffron R, Hall JE, Wise LA, Wegienka G, et al.* Depot Medroxyprogesterone Acetate Use and Blood Lead Levels in a Cohort of Young Women. *Environ Health Perspect.* 2020;128(11):117004. doi: 10.1289/EHP7017.
30. *Dianat S, Fox E, Ahrens KA, Upadhyay UD, Zlidar VM, Gallo MF, et al.* Side Effects and Health Benefits of Depot Medroxyprogesterone Acetate: A Systematic Review. *Obstet Gynecol.* 2019;133(2):332–41. doi: 10.1097/AOG.0000000000003089.
31. *Sorensen MB, Collins P, Ong PJJ, Webb CM, Hayward CS, Asbury EA, et al.* Long-Term Use of Contraceptive Depot Medroxyprogesterone Acetate in Young Women Impairs Arterial Endothelial Function Assessed by Cardiovascular Magnetic Resonance. *Circulation.* 2002;106(13):1646–51. doi: 10.1161/01.CIR.0000030940.73167.4E.
32. *Yadav BK, Gupta RK, Gyawali P, Shrestha R, Poudel B, Sigdel M, et al.* Effects of Long-term Use of Depo-medroxyprogesterone Acetate on Lipid Metabolism in Nepalese Women. *Korean Ann Lab Med.* 2011;31(2):95–7. doi: 10.3343/kjlm.2011.31.2.95.
33. *Witczak W, Kukulska A, Szeliga A, Podfigurna-stopa A, Niwczyk O.* Multiple complications associated with prolonged depot medroxyprogesterone acetate treatment. Case report and mini-review of literature. *Gynecol Reprod Endocrinol Metab.* 2023;3:107–11. doi: 10.53260/grem.22302038.
34. *Denayer T, Stöhr T, Roy M Van.* Animal models in translational medicine: Validation and prediction. *New Horizons in Translational Medicine* 2014;2(1):5–11. doi: 10.1016/j.nhtm.2014.08.001.
35. *Ramesh S, James MT, Holroyd-Leduc JM, Wilton SB, Seely EW, Wheeler DC, et al.* Sex Hormone Status in Women With Chronic Kidney Disease: Survey of Nephrologists' and Renal Allied Health Care Providers' Perceptions. *Can J Kidney Heal Dis.* 2017;4:205435811773453. doi: 10.1177/2054358117734534.